



Diagnosis of DVT

Antithrombotic Therapy and Prevention of Thrombosis, 9th ed: American College of Chest Physicians Evidence-Based Clinical Practice Guidelines

Shannon M. Bates, MDCM; Roman Jaeschke, MD; Scott M. Stevens, MD;
Steve Goodacre, MBChB, PhD; Philip S. Wells, MD; Matthew D. Stevenson, PhD;
Clive Kearon, MD, PhD; Holger J. Schunemann, MD, PhD, FCCP; Mark Crowther, MD;
Stephen G. Pauker, MD; Regina Makdissi, MD; and Gordon H. Guyatt, MD, FCCP

Background: Objective testing for DVT is crucial because clinical assessment alone is unreliable and the consequences of misdiagnosis are serious. This guideline focuses on the identification of optimal strategies for the diagnosis of DVT in ambulatory adults.

Methods: The methods of this guideline follow those described in *Methodology for the Development of Antithrombotic Therapy and Prevention of Thrombosis Guidelines: Antithrombotic Therapy and Prevention of Thrombosis, 9th ed: American College of Chest Physicians Evidence-Based Clinical Practice Guidelines*.

Results: We suggest that clinical assessment of pretest probability of DVT, rather than performing the same tests in all patients, should guide the diagnostic process for a first lower extremity DVT (Grade 2B). In patients with a low pretest probability of first lower extremity DVT, we recommend initial testing with D-dimer or ultrasound (US) of the proximal veins over no diagnostic testing (Grade 1B), venography (Grade 1B), or whole-leg US (Grade 2B). In patients with moderate pretest probability, we recommend initial testing with a highly sensitive D-dimer, proximal compression US, or whole-leg US rather than no testing (Grade 1B) or venography (Grade 1B). In patients with a high pretest probability, we recommend proximal compression or whole-leg US over no testing (Grade 1B) or venography (Grade 1B).

Conclusions: Favored strategies for diagnosis of first DVT combine use of pretest probability assessment, D-dimer, and US. There is lower-quality evidence available to guide diagnosis of recurrent DVT, upper extremity DVT, and DVT during pregnancy. *CHEST 2012; 141(2)(Suppl):e351S–e418S*

Abbreviations: aOR = adjusted OR; CUS = compression ultrasonography; GRADE = Grades of Recommendation, Assessment, Development, and Evaluation; IPG = impedance plethysmography; MR = magnetic resonance; PE = pulmonary embolism; US = ultrasonography

SUMMARY OF RECOMMENDATIONS

Note on Shaded Text: Throughout this guideline, shading is used within the summary of recommendations sections to indicate recommendations that are newly added or have been changed since the publication of *Antithrombotic and Thrombolytic Therapy: American College of Chest Physicians Evidence-Based Clinical Practice Guidelines (8th Edition)*. Recommendations that remain unchanged are not shaded.

3.1. In patients with a suspected first lower extremity DVT, we suggest that the choice of diagnostic tests process should be guided by the

clinical assessment of pretest probability rather than by performing the same diagnostic tests in all patients (Grade 2B).

Note: In considering this recommendation, five panels voted for a strong recommendation and four voted for a weak recommendation (one declined to vote and two did not participate). According to predetermined criteria, this resulted in weak recommendation.

3.2. In patients with a low pretest probability of first lower extremity DVT, we recommend one of the following initial tests: (i) a moderately sensitive D-dimer, (ii) a highly sensitive D-dimer,

or (iii) compression ultrasound (CUS) of the proximal veins rather than (i) no diagnostic testing (Grade 1B for all comparisons), (ii) venography (Grade 1B for all comparisons), or (iii) whole-leg ultrasound (US) (Grade 2B for all comparisons). We suggest initial use of a moderately sensitive (Grade 2C) or highly sensitive (Grade 2B) D-dimer rather than proximal CUS.

Remarks: The choice between a moderately sensitive D-dimer test, a highly sensitive D-dimer test, or proximal CUS as the initial test will depend on local availability, access to testing, costs of testing, and the probability of obtaining a negative D-dimer result if DVT is not present. Initial testing with US would be preferred if the patient has a comorbid condition associated with elevated D-dimer levels and is likely to have a positive D-dimer result, even if DVT is absent. In patients with suspected first lower extremity DVT in whom US is impractical (eg, when leg casting or excessive subcutaneous tissue or fluid prevent adequate assessment of compressibility) or nondiagnostic, we suggest CT scan venography or magnetic resonance (MR) venography, or MR direct thrombus imaging could be used as an alternative to venography.

If the D-dimer is negative, we recommend no further testing over further investigation with (i) proximal CUS, (ii) whole-leg US, or (iii) venog-

raphy (Grade 1B for all comparisons). **If the proximal CUS is negative, we recommend no further testing compared with (i) repeat proximal CUS after 1 week, (ii) whole-leg US, or (iii) venography** (Grade 1B for all comparisons).

If the D-dimer is positive, we suggest further testing with CUS of the proximal veins rather than (i) whole-leg US (Grade 2C) or (ii) venography (Grade 1B). If CUS of the proximal veins is positive, we suggest treating for DVT and performing no further testing over performing confirmatory venography (Grade 2C).

Remarks: In circumstances when high-quality venography is available, patients who are not averse to the discomfort of venography, are less concerned about the complications of venography, and place a high value on avoiding treatment of false-positive results are likely to choose confirmatory venography if findings for DVT are less certain (eg, a short segment of venous noncompressibility).

3.3. In patients with a moderate pretest probability of first lower extremity DVT, we recommend one of the following initial tests: (i) a highly sensitive D-dimer or (ii) proximal CUS, or (iii) whole-leg US rather than (i) no testing (Grade 1B for all comparisons) or (ii) venography (Grade 1B for all comparisons). We suggest initial use of a highly sensitive D-dimer rather than US (Grade 2C).

Remarks: The choice between a highly sensitive D-dimer test or US as the initial test will depend on local availability, access to testing, costs of testing, and the probability of obtaining a negative D-dimer result if DVT is not present. Initial testing with US may be preferred if the patient has a comorbid condition associated with elevated D-dimer levels and is likely to have a positive D-dimer result even if DVT is absent. Whole-leg US may be preferred in patients unable to return for serial testing and those with severe symptoms consistent with calf DVT. In patients with suspected first lower extremity DVT in whom US is impractical (eg, when leg casting or excessive subcutaneous tissue or fluid prevent adequate assessment of compressibility) or nondiagnostic, we suggest CT scan venography, MR venography, or MR direct thrombus imaging could be used as an alternative to venography.

If the highly sensitive D-dimer is negative, we recommend no further testing over further investigation with (i) proximal CUS, (ii) whole-leg US, or (iii) venography (Grade 1B for all comparisons). If the highly sensitive D-dimer is positive, we

Revision accepted August 31, 2011.

Affiliations: From the Department of Medicine (Drs Bates and Crowther), McMaster University and Thrombosis and Atherosclerosis Research Institute; the Departments of Medicine and Clinical Epidemiology and Biostatistics (Drs Jaeschke, Schunemann, and Guyatt), McMaster University, Hamilton, ON, Canada; the Department of Medicine (Dr Stevens), Intermountain Medical Center, Murray, UT; the School of Health and Related Research (Drs Goodacre and Stevenson), University of Sheffield, Sheffield, England; the Department of Medicine (Dr Wells), University of Ottawa, Ottawa, ON, Canada; the Department of Medicine (Dr Pauker), Tufts New England Medical Center, Boston, MA; and the Department of Medicine (Dr Makdissi), University of Buffalo, Buffalo, NY.

Funding/Support: The Antithrombotic Therapy and Prevention of Thrombosis, 9th ed: American College of Chest Physicians Evidence-Based Clinical Practice Guidelines received support from the National Heart, Lung, and Blood Institute [R13 HL104758] and Bayer Schering Pharma AG. Support in the form of educational grants was also provided by Bristol-Myers Squibb; Pfizer, Inc; Canyon Pharmaceuticals; and sanofi-aventis US.

Disclaimer: American College of Chest Physician guidelines are intended for general information only, are not medical advice, and do not replace professional medical care and physician advice, which always should be sought for any medical condition. The complete disclaimer for this guideline can be accessed at http://chestjournal.chestpubs.org/content/141/2_suppl/1S.

Correspondence to: Shannon M. Bates, MDCM, HSC 3W11, Department of Medicine, 1280 Main St W, Hamilton, ON, L8S 4K1, Canada; e-mail: batesm@mcmaster.ca

© 2012 American College of Chest Physicians. Reproduction of this article is prohibited without written permission from the American College of Chest Physicians (<http://www.chestpubs.org/site/misc/reprints.xhtml>).

DOI: 10.1378/chest.11-2299

recommend proximal CUS or whole-leg US rather than no testing (Grade 1B for all comparisons) **or venography** (Grade 1B for all comparisons).

If proximal CUS is chosen as the initial test and is negative, we recommend (i) repeat proximal CUS in 1 week or (ii) testing with a moderate or highly sensitive D-dimer assay over no further testing (Grade 1C) **or venography** (Grade 2B). **In patients with a negative proximal CUS but a positive D-dimer, we recommend repeat proximal CUS in 1 week over no further testing** (Grade 1B) **or venography** (Grade 2B).

In patients with (i) negative serial proximal CUS or (ii) a negative single proximal CUS and negative moderate or highly sensitive D-dimer, we recommend no further testing rather than further testing with (i) whole-leg US or (ii) venography (Grade 1B for all comparisons).

If whole-leg US is negative, we recommend no further testing over (i) repeat US in one week, (ii) D-dimer testing, or (iii) venography (Grade 1B for all comparisons). **If proximal CUS is positive, we recommend treating for DVT rather than confirmatory venography** (Grade 1B). **If isolated distal DVT is detected on whole-leg US, we suggest serial testing to rule out proximal extension over treatment** (Grade 2C).

Remarks: Patients with abnormal isolated distal US findings on whole-leg US who place a high value on avoiding the inconvenience of repeat testing and a low value on avoiding treatment of false-positive results are likely to choose treatment over repeat US. Patients with severe symptoms and risk factors for extension as outlined in Perioperative Management of Antithrombotic Therapy. Antithrombotic Therapy and Prevention of Thrombosis, 9th ed: American College of Chest Physicians Evidence-Based Clinical Practice Guidelines are more likely to benefit from treatment over repeat US.

3.4. In patients with a high pretest probability of first lower extremity DVT, we recommend either (i) proximal CUS or (ii) whole-leg US over no testing (Grade 1B for all comparisons) **or venography** (Grade 1B for all comparisons).

Remarks: Whole-leg US may be preferred to proximal CUS in patients unable to return for serial testing and those with severe symptoms consistent with calf DVT. In patients with extensive unexplained leg swelling, if there is no DVT on proximal CUS or whole-leg US and D-dimer testing has not been performed or is positive, the iliac veins should be

imaged to exclude isolated iliac DVT. In patients with suspected first lower extremity DVT in whom US is impractical (eg, when leg casting or excessive subcutaneous tissue or fluid prevent adequate assessment of compressibility) or nondiagnostic, we suggest CT scan venography, MR venography, or MR direct thrombus imaging could be used as an alternative to venography.

If proximal CUS or whole-leg US is positive for DVT, we recommend treatment rather than confirmatory venography (Grade 1B).

In patients with a negative proximal CUS, we recommend additional testing with a highly sensitive D-dimer or whole-leg US or repeat proximal CUS in 1 week over no further testing (Grade 1B for all comparisons) **or venography** (Grade 2B for all comparisons). **We recommend that patients with a single negative proximal CUS and positive D-dimer undergo whole-leg US or repeat proximal CUS in 1 week over no further testing** (Grade 1B) **or venography** (Grade 2B). **In patients with negative serial proximal CUS, a negative single proximal CUS and negative highly sensitive D-dimer, or a negative whole-leg US, we recommend no further testing over venography or additional US** (Grade 1B for negative serial proximal CUS and for negative single proximal CUS and highly sensitive D-dimer; Grade 2B for negative whole-leg US).

We recommend that in patients with high pretest probability, moderately or highly sensitive D-dimer assays should not be used as stand-alone tests to rule out DVT (Grade 1B).

3.5. If risk stratification is not performed in patients with suspected first lower extremity DVT, we recommend one of the following initial tests: (i) proximal CUS or (ii) whole-leg US rather than (i) no testing (Grade 1B), **(ii) venography** (Grade 1B), **or D-dimer testing** (Grade 2B).

Remarks: Whole-leg US may be preferred to proximal CUS in patients unable to return for serial testing and those with severe symptoms consistent with calf DVT or risk factors for extension of distal DVT. In patients with suspected first lower extremity DVT in whom US is impractical (eg, when leg casting or excessive subcutaneous tissue or fluid prevent adequate assessment of compressibility) or nondiagnostic, we suggest that CT scan venography, MR venography, or MR direct thrombus imaging could be used as an alternative to venography.

We recommend that patients with a negative proximal CUS undergo testing with a moderate- or

high-sensitivity D-dimer, whole-leg US, or repeat proximal CUS in 1 week over no further testing (Grade 1B) or venography (Grade 2B). In patients with a negative proximal CUS, we suggest D-dimer rather than routine serial CUS (Grade 2B) or whole-leg US (Grade 2C). We recommend that patients with a single negative proximal CUS and positive D-dimer undergo further testing with repeat proximal CUS in 1 week or whole-leg US rather than no further testing (Grade 1B for both comparisons).

We recommend that in patients with (i) negative serial proximal CUS, (ii) a negative D-dimer following a negative initial proximal CUS, or (iii) negative whole-leg US, no further testing be performed rather than venography (Grade 1B).

If proximal US is positive for DVT, we recommend treatment rather than confirmatory venography (Grade 1B). If isolated distal DVT is detected on whole-leg US, we suggest serial testing to rule out proximal extension over treatment (Grade 2C).

Remarks: Patients with abnormal isolated distal US findings on whole-leg US who place a high value on avoiding the inconvenience of repeat testing and a low value on avoiding treatment of false-positive results are likely to choose treatment over repeat US. Patients with severe symptoms and risk factors for extension as outlined in Perioperative Management of Antithrombotic Therapy. Antithrombotic Therapy and Prevention of Thrombosis, 9th ed: American College of Chest Physicians Evidence-Based Clinical Practice Guidelines are more likely to benefit from treatment over repeat US.

3.6. In patients with suspected first lower extremity DVT, we recommend against the routine use of CT venography or MRI (Grade 1C).

4.1. In patients suspected of having recurrent lower extremity DVT, we recommend initial evaluation with proximal CUS or a highly sensitive D-dimer over venography, CT venography, or MRI (all Grade 1B).

Remarks: Initial D-dimer testing with a high-sensitivity assay is preferable if prior US is not available for comparison.

If the highly sensitive D-dimer is positive, we recommend proximal CUS over venography, CT venography, or MRI (Grade 1B for all comparisons).

In patients with suspected recurrent lower extremity DVT in whom initial proximal CUS is negative (normal or residual diameter increase

of < 2 mm), we suggest at least one further proximal CUS (day 7 ± 1) or testing with a moderately or highly sensitive D-dimer (followed by repeat CUS [day 7 ± 1] if positive) rather than no further testing or venography (Grade 2B).

Remarks: In patients with an abnormal proximal CUS at presentation that does not meet the criteria for the diagnosis of recurrence, an additional proximal CUS on day 2 ± 1 in addition to that on (day 7 ± 1) may be preferred. Patients who place a high value on an accurate diagnosis and a low value on avoiding the inconvenience and potential side effects of a venography are likely to choose venography over missed diagnosis (in the case of residual diameter increase of < 2 mm).

We recommend that patients with suspected recurrent lower extremity DVT and a negative highly sensitive D-dimer or negative proximal CUS and negative moderately or highly sensitive D-dimer or negative serial proximal CUS undergo no further testing for suspected recurrent DVT rather than venography (Grade 1B).

If CUS of the proximal veins is positive, we recommend treating for DVT and performing no further testing over performing confirmatory venography (Grade 1B for the finding of a new non-compressible segment in the common femoral or popliteal vein, Grade 2B for a ≥ 4 -mm increase in venous diameter during compression compared with that in the same venous segment on a previous result).

Remarks: Patients with US abnormalities at presentation that do not include a new noncompressible segment who place a high value on an accurate diagnosis and a low value on avoiding the inconvenience and potential side effects of a venography are likely to choose venography over treatment (in the case of ≥ 4 -mm increase in venous diameter).

4.2. In patients with suspected recurrent lower extremity DVT and abnormal but nondiagnostic US results (eg, an increase in residual venous diameter of < 4 but ≥ 2 mm), we recommend further testing with venography, if available (Grade 1B); serial proximal CUS (Grade 2B) or testing with a moderately or highly sensitive D-dimer with serial proximal CUS as above if the test is positive (Grade 2B), as opposed to other testing strategies or treatment.

4.3. In patients with suspected recurrent ipsilateral DVT and an abnormal US without a prior result for comparison, we recommend further

testing with venography, if available (Grade 1B) or a highly sensitive D-dimer (Grade 2B) over serial proximal CUS. In patients with suspected recurrent ipsilateral DVT and an abnormal US without prior result for comparison and a negative highly sensitive D-dimer, we suggest no further testing over venography (Grade 2C). In patients with suspected recurrent ipsilateral DVT and an abnormal US without prior result for comparison and a positive highly sensitive D-dimer, we suggest venography if available over empirical treatment of recurrence (Grade 2C).

Remarks: Patients who place a high value on avoiding the inconvenience and potential side effects of a venography are likely to choose treatment over venography.

5.1. In pregnant patients suspected of having lower extremity DVT, we recommend initial evaluation with proximal CUS over other initial tests, including a whole-leg US (Grade 2C), moderately sensitive D-dimer (Grade 2C), highly sensitive D-dimer (Grade 1B), or venography (Grade 1B).

5.2. In pregnant patients with suspected DVT in whom initial proximal CUS is negative, we suggest further testing with either serial proximal CUS (day 3 and day 7) (Grade 1B) or a sensitive D-dimer done at the time of presentation (Grade 2B) over no further testing for DVT. We recommend that patients with an initial negative proximal CUS and a subsequent negative sensitive D-dimer or negative serial proximal CUS undergo no further testing for DVT (Grade 1B) and that patients with positive D-dimer have an additional follow-up proximal CUS (day 3 and day 7) rather than venography (Grade 1B) or whole-leg US (Grade 2C).

5.3. In pregnant patients with symptoms suggestive of isolated iliac vein thrombosis (swelling of the entire leg, with or without flank, buttock, or back pain) and no evidence of DVT on standard proximal CUS, we suggest further testing with either Doppler US of the iliac vein (Grade 2C), venography (Grade 2C), or direct MRI (Grade 2C), rather than standard serial CUS of the proximal deep veins.

6.1. In patients suspected of having upper extremity DVT, we suggest initial evaluation with combined modality US (compression with either Doppler or color Doppler) over other initial tests, including highly sensitive D-dimer or venography (Grade 2C).

6.2. In patients with suspected upper extremity DVT in whom initial US is negative for thrombosis despite a high clinical suspicion of DVT, we suggest further testing with a moderate or highly sensitive D-dimer, serial US, or venographic-based imaging (traditional, CT scan, or MRI), rather than no further testing (Grade 2C).

In patients with suspected upper extremity DVT and an initial negative combined-modality US and subsequent negative moderate or highly sensitive D-dimer or CT or MRI, we recommend no further testing, rather than confirmatory venography (Grade 1C). We suggest that patients with an initial combined negative modality US and positive D-dimer or those with less than complete evaluation by US undergo venography rather than no further testing, unless there is an alternative explanation for their symptoms (Grade 2B), in which case testing to evaluate for the presence an alternative diagnosis should be performed. We suggest that patients with a positive D-dimer or those with less than complete evaluation by US but an alternative explanation for their symptoms undergo confirmatory testing and treatment of this alternative explanation rather than venography (Grade 2C).

Remarks: Further radiologic testing (serial US or venographic-based imaging or CT/MR to seek an alternative diagnosis) rather than D-dimer testing is preferable in patients with comorbid conditions typically associated with elevated D-dimer levels.

DVT is a common condition that affects approximately one in 1,000 persons per year.^{1,2} Objective testing for DVT is crucial because clinical assessment alone is unreliable,³⁻⁶ and the consequences of misdiagnosis are serious, including fatal pulmonary embolism (PE).^{7,8} Although anticoagulant therapy is effective,⁹ its unnecessary use entails expense, inconvenience, and risk of major hemorrhage.⁹ Only a minority of patients evaluated for suspected DVT actually have the disease.¹⁰ Therefore, diagnostic strategies must be able to correctly rule in DVT when it is present and safely rule out DVT when it is absent.

Three categories of tests are typically used to determine the probability of DVT: (1) clinical probability assessment based on patient history and clinical findings, (2) D-dimer assays, and (c) imaging studies (most commonly venous ultrasonography [US] and less frequently venography, CT scan, or MRI). Diagnostic testing often requires that the results of more than one assessment are combined. The goal of choosing one strategy over another is to improve patient outcomes in the most efficient manner.

This article focuses on the identification of optimal strategies for the diagnosis of clinically suspected DVT in adults. Consecutive sections of this chapter concentrate on first DVT, recurrent DVT, upper extremity DVT, and DVT during pregnancy. Most of the data come from evaluations of patients in the ambulatory setting (ie, outpatient or ED), and our recommendations are most applicable to this patient population. Recommendations for the treatment of DVT once diagnosed can be found in Kearon et al.¹¹

1.0 METHODS

Article panelists identified questions related to the evaluation of adults with suspected DVT (Table 1). A broad overview search was performed centrally and provided to all coauthors, who followed it with more specific searching as required. Recommendations were developed from this evidence.

Eligible studies included both those addressing diagnostic accuracy (cross-sectional accuracy studies) and studies that assessed clinical outcomes such as DVT or PE during follow-up (prospective cohort management studies and randomized controlled trials [RCTs]). In typical management studies, investigators follow untreated patients with negative test results and record the proportion of patients who develop VTE. For each section, we developed corresponding methodology tables that included information on the study question (in terms of population, intervention, comparator, and outcome), the type of evidence assessed (meta-analysis or original study; cross-sectional study or management cohort or randomized trial), and selected details of study execution (inclusion of consecutive patients and independence of test result assessment). Findings of individual studies and meta-analyses are presented in descriptive tables and, when feasible, overall findings relating to each question are summarized as Evidence Profiles and Summary of Findings tables.

For accuracy studies, we extracted sensitivity and specificity and then estimated the effect on patient-important outcomes (eg, DVT, PE, death, bleeding in treated patients) that would be associated with this level of accuracy, assuming prevalences of DVT that correspond to high, moderate, and low pretest probability categories. For studies in which the diagnostic test was used to manage patients (ie, management studies), the incidence of VTE during follow-up was determined for patients in whom anticoagulation and additional diagnostic testing were withheld on the basis of negative test results.

Following the approach articulated by Grades of Recommendation, Assessment, Development, and Evaluation (GRADE) for formulation of recommendations related to diagnosis,¹² we first considered the quality of evidence (representing our confidence that the testing strategy would result in patient outcomes that support a particular recommendation). We initially considered studies as providing high quality of evidence, unless rated down because of the following factors: risk of bias (eg, unrepresentative patients, lack of independent assessment of test and criterion standard), inconsistency (differences among study results), indirectness (with respect to the population studied, the tests performed, or the outcome measured), lack of precision, and risk of publication bias. Unless otherwise explicitly stated, the quality of evidence obtained from cross-sectional accuracy studies was lowered by one level because of the indirectness with which sensitivity and specificity corresponds to patient-important outcomes.

Typically, diagnostic strategies for DVT have been deemed acceptable if they have demonstrated no more than a 2% frequency

of VTE during follow-up (a rate comparable to that seen when DVT is excluded by venography) in management studies in which treatment is withheld on the basis of a negative result.¹³ Management studies that assess the follow-up frequency of VTE after negative diagnostic testing provide no information regarding false-positive diagnoses for DVT. Patients who are misdiagnosed with DVT will be prescribed unnecessary anticoagulants and some will suffer major bleeding as a result.

To overcome this limitation, we estimated the risk of major bleeding associated with different diagnostic strategies. These estimates were based on (1) the proportion of patients diagnosed with DVT (derived from sensitivity and specificity, with the assumption that all diagnosed DVT are treated), and (2) the frequency of major bleeding with 3 months of therapeutic-dose anticoagulants in cohort studies and randomized trials of patients with VTE. Because the evidence regarding major bleeding emerging from these models is indirect, it is generally rated as no higher than moderate quality.

For those diagnostic tests that have been robustly evaluated in management studies (ie, in patients with suspected first lower extremity DVT), we have assessed the impact of various strategies on major bleeding (both fatal and nonfatal, in patients prescribed anticoagulants on the basis of a positive test result) and mortality, as well as on the frequency of PE during follow-up (fatal and nonfatal) after application of a given diagnostic strategy (see Table S1 for list of strategies) (tables that contain an “S” before the number denote supplementary tables not contained in the body of the article and available instead in an online data supplement; see the “Acknowledgments” for more information). Management studies that followed cohorts of patients subjected to specific strategies for DVT diagnosis were used to determine the proportion of patients initially judged to be DVT-free who returned with symptomatic VTE. In order to identify the proportion and clinical course of patients incorrectly classified as having DVT and to estimate the risk of PE (fatal and nonfatal) in patients incorrectly categorized, we used a decision analytic model based on methodology described in detail in previous publications.^{14,15} The model was originally developed to estimate the cost-effectiveness of diagnostic strategies. It was updated to include estimates of the outcomes (see below) of patients with DVT treated with anticoagulation for at least 3 months reported in a recent meta-analysis.⁹ Sensitivities and specificities from meta-analyses were used to determine the proportion of patients with proximal, distal, and no DVT subjected to each diagnostic strategy who would be treated with anticoagulant therapy.

Based on the results of a previous meta-analysis of patients with suspected symptomatic DVT of the leg, we estimated an overall prevalence of proximal DVT of 19.0%,¹⁰ with prevalences of 56.2%, 12.4%, and 3.4% in the high, moderate, and low pretest probability groups, respectively. The overall prevalence of distal DVT was estimated to be 5%. Untreated distal DVT was assumed not to directly cause PE; we estimated the probability of propagation to proximal veins of 21.4%. We estimated the probability that patients with treated proximal DVT would suffer a fatal PE to be 0.3% and a nonfatal PE to be 1.4% over 3 months.

The model assumed that all bleeding events were attributable to anticoagulation (ie, bleeding rates are not reported for untreated patients). Patients receiving treatment had a 0.3% probability of fatal bleeding, a 0.1% probability of nonfatal intracranial bleeding, and a 2.1% probability of major nonfatal non-intracranial bleeding over 3 months.^{9,14,15} All parameters were modeled with a probability distribution to generate a credible range for the outcomes in question. The outputs from the model were the proportion of patients suffering the following events over the 3 months after diagnostic assessment: (1) fatal PE, (2) nonfatal PE, (3) fatal bleeding, (4) nonfatal intracranial bleeding, and (5) major nonfatal, non-intracranial bleeding. Table S1 lists the 21 diagnostic algorithms evaluated with this model.¹⁶⁻³⁵

Table 1—Structured Clinical Questions

Informal Question	PICO Question				Methodology
	Population	Intervention	Comparator	Outcome	
	Suspected first DVT (Section 3.0)				
What are the consequences of using venography to diagnose first DVT?	Patients with suspected first DVT	Persistent intraluminal filling defect		Morbidity caused by test strategy Number of nonevaluable test results	RCTs Observational studies Prospective cohort studies (can be single group or single arm that used diagnostic intervention specified in question) Cross-sectional accuracy studies (if insufficient data from randomized controlled management trials or prospective management studies)
What are the consequences of using venography to rule out first DVT?	Patients with suspected first DVT	Negative venography	VTE during additional testing or 3-6 mo follow-up if intervention negative for DVT	FN/1,000 of negatives (eg, post-TP of a negative test) Morbidity caused by test strategy	RCTs Observational studies Prospective cohort studies (can be single group or single arm that used diagnostic intervention specified in question) Cross-sectional accuracy studies (if insufficient data from randomized controlled management trials or prospective management studies)
What are the consequences of using CUS to diagnose proximal DVT	Patients with suspected first DVT	Noncompressible venous segment from common femoral vein down to and including the trifurcation veins In all patients If low pre-TP If moderate pre-TP If high pre-TP If positive highly sensitive DD If positive moderately sensitive (SimpliRED) DD If negative highly sensitive DD If negative moderately sensitive (SimpliRED) DD	Venography	FP/1,000 of positive (eg, post-TP of a positive test) if management study Specificity if accuracy study Morbidity caused by test strategy	RCTs Observational studies Prospective cohort studies (can be single group or single arm that used diagnostic intervention specified in question) Cross-sectional accuracy studies (if insufficient data from randomized controlled management trials or prospective management studies)

(Continued)

Table 1—Continued

Informal Question	PICO Question				Methodology
	Population	Intervention	Comparator	Outcome	
What are the consequences of using serial proximal CUS to exclude DVT (regardless of pre-TP)?	Patients with suspected first DVT	Proximal CUS on presentation and if negative a follow-up test approximately 1 wk later	Venography or VTE during additional testing or 3-6 mo follow-up if intervention negative for DVT	FN/1,000 of negatives (eg, post-TP of a negative test) if management study Sensitivity if accuracy study Morbidity caused by test strategy	RCTs Observational studies Prospective cohort studies (can be single group or single arm that used diagnostic intervention specified in question) Cross-sectional accuracy studies (if insufficient data from randomized controlled management trials or prospective management studies)
What are the consequences of using whole-leg US to diagnose distal DVT	Patients with suspected first DVT	Noncompressible venous segment isolated to the calf veins (eg, posterior tibial, anterior tibial, and peroneal veins) In all patients If low pre-TP If moderate pre-TP If high pre-TP If positive highly sensitive DD If positive moderately sensitive (SimpliRED) DD If negative highly sensitive DD If negative moderately sensitive DD	Venography or serial proximal CUS plus VTE during additional 3-6 mo if negative for proximal DVT	FP/1,000 of positive (eg, post-TP of a positive test) if management study Specificity if accuracy study Morbidity caused by test strategy	RCTs Observational studies Prospective cohort studies (can be single group or single arm that used diagnostic intervention specified in question) Cross-sectional accuracy studies (if insufficient data from randomized controlled management trials or prospective management studies)
What are the consequences of using a single whole-leg US to exclude DVT (regardless of pre-TP)?	Patients with suspected first DVT	Negative single whole-leg US on day of presentation	Venography or serial proximal CUS plus VTE during additional 3-6 mo if negative for proximal DVT	FN/1,000 of negatives (eg, post-TP of a negative test) Sensitivity if accuracy study Morbidity caused by test strategy	RCTs Observational studies Prospective cohort studies (can be single group or single arm that used diagnostic intervention specified in question) Cross-sectional accuracy studies (if insufficient data from randomized controlled management trials or prospective management studies)

(Continued)

Table 1—Continued

PICO Question					
Informal Question	Population	Intervention	Comparator	Outcome	
What are the consequences of using a highly sensitive DD as a stand-alone test to exclude DVT?	Patients with suspected first DVT	Negative highly sensitive DD on day of presentation	Venography or serial proximal CUS plus VTE during additional 3-6 mo if negative for proximal DVT	FN/1,000 of negatives (eg, post-TP of a negative test) Sensitivity if accuracy study Morbidity caused by test strategy	RCTs Observational studies Prospective cohort studies (can be single group or single arm that used diagnostic intervention specified in question) Cross-sectional accuracy studies (if insufficient data from randomized controlled management trials or prospective management studies)
What are the consequences of using DD and pre-TP to exclude DVT?	Patients with suspected first DVT	Negative moderately sensitive (Simplified) DD plus low/moderate/high pre-TP at presentation or Negative highly sensitive DD plus low/moderate/high pre-TP at presentation	Venography or serial proximal CUS plus VTE during additional 3-6 mo if negative for proximal DVT	FN/1,000 of negatives (eg, post-TP of a negative test) Sensitivity if accuracy study Morbidity caused by test strategy	RCTs Observational studies Prospective cohort studies (can be single group or single arm that used diagnostic intervention specified in question) Cross-sectional accuracy studies (if insufficient data from randomized controlled management trials or prospective management studies)
What are the consequences of using a negative proximal CUS and negative DD to exclude DVT?	Patients with suspected first DVT	Negative moderately sensitive (Simplified) DD plus negative proximal CUS at presentation or Negative highly sensitive plus negative proximal CUS at presentation	Venography or serial proximal CUS plus VTE during additional 3-6 mo if negative for proximal DVT	FN/1,000 of negatives (eg, post-TP of a negative test) Sensitivity if accuracy study Morbidity caused by test strategy	RCTs Observational studies Prospective cohort studies (can be single group or single arm that used diagnostic intervention specified in question) Cross-sectional accuracy studies (if insufficient data from randomized controlled management trials or prospective management studies)
What are the consequences of using pre-TP with a negative proximal CUS to exclude DVT?	Patients with suspected first DVT	Negative proximal CUS plus low/moderate/high pre-TP at presentation	Venography or serial proximal CUS plus VTE during additional 3-6 mo if negative for proximal DVT	FN/1,000 of negatives (eg, post-TP of a negative test) Sensitivity if accuracy study Morbidity caused by test strategy	RCTs Observational studies Prospective cohort studies (can be single group or single arm that used diagnostic intervention specified in question) Cross-sectional accuracy studies (if insufficient data from randomized controlled management trials or prospective management studies)

(Continued)

Table 1—Continued

Informal Question	PICO Question				Methodology
	Population	Intervention	Comparator	Outcome	
What are the consequences of using serial proximal CUS to exclude DVT in patients with a low/moderate/high pre-TP?	Patients with suspected first DVT	Repeat proximal CUS (within approximately 1 wk)	Venography or serial proximal CUS plus VTE during additional 3-6 mo if negative for proximal DVT	FN/1,000 of negatives (eg, post-TP of a negative test) Sensitivity if accuracy study Morbidity caused by test strategy	RCTs Observational studies Prospective cohort studies (can be single group or single arm that used diagnostic intervention specified in question) Cross-sectional accuracy studies (if insufficient data from randomized controlled management trials or prospective management studies)
What are the consequences of using serial proximal CUS to exclude DVT in patients with a positive DD? Negative proximal CUS plus positive moderately sensitive (SimpliRED) or highly sensitive DD plus low pre-TP Negative proximal CUS plus positive moderately sensitive (SimpliRED) or highly sensitive DD plus moderate pre-TP Negative proximal CUS plus positive highly sensitive DD plus high pre-TP	Patients with suspected first DVT	Repeat proximal CUS (within approximately 1 wk)	Venography or serial proximal CUS plus VTE during additional 3-6 mo if negative for proximal DVT	FN/1,000 of negatives (eg, post-TP of a negative test) Sensitivity if accuracy study Morbidity caused by test strategy	RCTs Observational studies Prospective cohort studies (can be single group or single arm that used diagnostic intervention specified in question) Cross-sectional accuracy studies (if insufficient data from randomized controlled management trials or prospective management studies)
What are the consequences of using a negative DD to obviate the need for serial testing in patients with a negative proximal CUS and moderate or high pre-TP at presentation? Negative proximal CUS plus moderate pre-TP Negative proximal CUS plus high pre-TP	Patients with suspected first DVT	Negative highly sensitive DD or negative moderately sensitive (SimpliRED) DD	Venography or serial proximal CUS plus VTE during additional 3-6 mo if negative for proximal DVT	FN/1,000 of negatives (eg, post-TP of a negative test) Sensitivity if accuracy study Morbidity caused by test strategy	RCTs Observational studies Prospective cohort studies (can be single group or single arm that used diagnostic intervention specified in question) Cross-sectional accuracy studies (if insufficient data from randomized controlled management trials or prospective management studies)

(Continued)

Table 1—Continued

		PICO Question					
Informal Question	Population	Intervention	Comparator	Outcome	RCTs	Methodology	
What are the consequences of using CT scan venography to diagnose DVT	Patients with suspected first DVT	Intraluminal filling defect	Venography or serial proximal CUS plus VTE during additional 3-6 mo if negative for proximal DVT or single whole-leg US plus VTE during additional 3-6 mo if negative for DVT	FP/1,000 of positive (eg, post-TP of a positive test) if management study Specificity if accuracy study Morbidity caused by test strategy	Observational studies Prospective cohort studies (can be single group or single arm that used diagnostic intervention specified in question) Cross-sectional accuracy studies (if insufficient data from randomized controlled management trials or prospective management studies)		
What are the consequences of using CT scan venography to exclude DVT?	Patients with suspected first DVT	Negative CT scan venography	Venography or VTE during additional testing or 3-6 mo follow-up if intervention negative for DVT	FN/1,000 of negatives (eg, post-TP of a negative test) if management study Sensitivity if accuracy study Morbidity caused by test strategy	RCTs Observational studies Prospective cohort studies (can be single group or single arm that used diagnostic intervention specified in question) Cross-sectional accuracy studies (if insufficient data from randomized controlled management trials or prospective management studies)		
What are the consequences of using contrast MR venography to diagnose DVT?	Patients with suspected first DVT	Intraluminal filling defect	Venography or serial proximal CUS plus VTE during additional 3-6 mo if negative for whole-leg US plus VTE during additional 3-6 mo if negative for DVT	FP/1,000 of positive (eg, post-TP of a positive test) if management study Specificity if accuracy study Morbidity caused by test strategy	RCTs Observational studies Prospective cohort studies (can be single group or single arm that used diagnostic intervention specified in question) Cross-sectional accuracy studies (if insufficient data from randomized controlled management trials or prospective management studies)		
What are the consequences of using contrast MR venography to exclude DVT?	Patients with suspected first DVT	Negative MR venography	Venography or VTE during additional testing or 3-6 mo follow-up if intervention negative for DVT	FN/1,000 of negatives (eg, post-TP of a negative test) if management study Sensitivity if accuracy study Morbidity caused by test strategy	RCTs Observational studies Prospective cohort studies (can be single group or single arm that used diagnostic intervention specified in question) Cross-sectional accuracy studies (if insufficient data from randomized controlled management trials or prospective management studies)		
What are the consequences of using MR direct thrombus imaging to diagnose DVT	Patients with suspected first DVT	High signal intensity	Venography or serial proximal CUS plus VTE during additional 3-6 mo if negative for proximal DVT or single whole-leg US plus VTE during additional 3-6 mo if negative for DVT	FP/1,000 of positive (eg, post-TP of a positive test) if management study Specificity if accuracy study Morbidity caused by test strategy	RCTs Observational studies Prospective cohort studies (can be single group or single arm that used diagnostic intervention specified in question) Cross-sectional accuracy studies (if insufficient data from randomized controlled management trials or prospective management studies)		

(Continued)

Table 1—Continued

		PICO Question			
Informal Question	Population	Intervention	Comparator	Outcome	Methodology
What are the consequences of using MR direct thrombus imaging to exclude DVT?	Patients with suspected first DVT	Negative MR direct thrombus imaging	Venography or VTE during additional testing or 3-6 mo follow-up if intervention negative for DVT	FN/1,000 of negatives (eg, post-TP of a negative test) if management study Sensitivity if accuracy study Morbidity caused by test strategy	RCTs Observational studies Prospective cohort studies (can be single group or single arm that used diagnostic intervention specified in question) Cross-sectional accuracy studies (if insufficient data from randomized controlled management trials or prospective management studies)
Suspected recurrent DVT (Section 4.0)					
What are the consequences of using venography to diagnose recurrent DVT?	Patients with suspected recurrent DVT	Persistent intraluminal filling defect		Morbidity caused by test strategy Number of nonevaluable tests	RCTs Observational studies Prospective cohort studies (can be single group or single arm that used diagnostic intervention specified in question) Cross-sectional accuracy studies (if insufficient data from randomized controlled management trials or prospective management studies)
What are the consequences of using venography to rule out recurrent DVT?	Patients with suspected recurrent DVT	Negative venography or venography with no new intraluminal filling defects	VTE during additional testing or 3-6 mo follow-up if intervention shows no evidence of recurrence	FN/1,000 (eg, post-TP of a negative test) Morbidity caused by test strategy	RCTs Observational studies Prospective cohort studies (can be single group or single arm that used diagnostic intervention specified in question) Cross-sectional accuracy studies (if insufficient data from randomized controlled management trials or prospective management studies)
What are the consequences of using serial proximal CUS to diagnose recurrent DVT in the presence of the following?	Patients with suspected recurrent DVT		Venography	FP/1,000 of positive (eg, post-TP of a positive test) if management study Specificity if accuracy study Morbidity caused by test strategy	RCTs Observational studies Prospective cohort studies (can be single group or single arm that used diagnostic intervention specified in question) Cross-sectional accuracy studies (if insufficient data from randomized controlled management trials or prospective management studies)

(Continued)

Table 1—Continued

Informal Question	PICO Question			Methodology
	Population	Intervention	Comparator	
New noncompressible segment		New noncompressible segment compared with previous proximal CUS either at presentation or on follow-up test(s) over next 7-10 d		
Increase in residual venous diameter		New increase in residual venous diameter greater than specified compared with previous proximal CUS either at presentation or on follow-up test(s) over next 7-10 d		
New noncompressible segment or increase in residual venous diameter		New noncompressible segment or change in residual diameter greater than specified compared with previous proximal CUS at presentation or on follow-up test(s) over next 7-10 d		
What are the consequences of using serial proximal CUS to exclude recurrent DVT in the absence of the following?	Patients with suspected recurrent DVT		Venography or VTE during additional testing or 3-6 mo follow-up if intervention shows no evidence of recurrence	RCTs Observational studies Prospective cohort studies (can be single group or single arm that used diagnostic intervention specified in question) Cross-sectional accuracy studies (if insufficient data from randomized controlled management trials or prospective management studies)
New noncompressible segment		Proximal CUS on presentation and if negative or no new noncompressible segment compared with previous, follow-up test(s) over next 5-10 d, examining for new noncompressible segment	FN/1,000 (eg, post-TP of a negative test) if management study Sensitivity if accuracy study Morbidity caused by test strategy	

(Continued)

Table 1—Continued

Informal Question	PICO Question				Methodology
	Population	Intervention	Comparator	Outcome	
Change in residual venous diameter		Proximal CUS on presentation and if negative or change in residual venous diameter less than specified compared with previous, follow-up test(s) over next 5-10 d, examining for change in residual venous diameter			
New noncompressible segment or change in residual venous diameter		Proximal CUS on presentation and if negative or no new noncompressible segment or change in residual diameter greater than specified compared with previous, follow-up test(s) over next 5-10 d, examining for new noncompressible segment or change in residual venous diameter			
What are the consequences of using DD and pre-TP to exclude suspected recurrent DVT?	Patients with suspected recurrent DVT	Negative moderately sensitive (Simplified) DD plus low/moderate/high pre-TP at presentation OR Negative highly sensitive DD plus low/moderate/high pre-TP at presentation	Venography or VTE during additional testing or 3-6 mo follow-up if intervention shows no evidence of recurrence	FN/1,000 (eg, post-TP of a negative test) if management study Sensitivity if accuracy study Morbidity caused by test strategy	RCTs Observational studies Prospective cohort studies (can be single group or single arm that used diagnostic intervention specified in question) Cross-sectional accuracy studies (if insufficient data from randomized controlled management trials or prospective management studies)

(Continued)

Table 1—Continued

Informal Question		PICO Question			Outcome	Methodology
	Population	Intervention	Comparator			
What are the consequences of using a negative DD and proximal CUS (or proximal CUS unchanged from previous with respect to noncompressible segment and/or residual venous diameter) to exclude recurrent DVT?	Patients with suspected recurrent DVT	Negative moderately sensitive (SimpliRED) DD plus negative/unchanged (with respect to noncompressible segments and/or residual venous diameter) proximal CUS at presentation or Negative highly sensitive DD plus negative proximal CUS (with respect to noncompressible segments and/or residual venous diameter) at presentation	Venography or VTE during additional testing or 3-6 mo follow-up if intervention shows no evidence of recurrence	FN/1,000 (eg, post-TP of a negative test) if management study Sensitivity if accuracy study Morbidity caused by test strategy	RCTs Observational studies Prospective cohort studies (can be single group or single arm that used diagnostic intervention specified in question) Cross-sectional accuracy studies (if insufficient data from randomized controlled management trials or prospective management studies)	
What are the consequences of using a negative DD to exclude recurrent DVT?	Patients with suspected recurrent DVT	Negative moderately sensitive (SimpliRED) or Negative highly sensitive DD	Venography or VTE during additional testing or 3-6 mo follow-up if intervention shows no evidence of recurrence	FN/1,000 (eg, post-TP of a negative test) if management study Sensitivity if accuracy study Morbidity caused by test strategy	RCTs Observational studies Prospective cohort studies (can be single group or single arm that used diagnostic intervention specified in question) Cross-sectional accuracy studies (if insufficient data from randomized controlled management trials or prospective management studies)	
What are the consequences of using CT scan venography to diagnose recurrent DVT?	Patients with suspected recurrent DVT	Intraluminal filling defect	Venography	FP/1,000 of positive (eg, post-TP of a positive test) if management study Specificity if accuracy study Morbidity caused by test strategy	RCTs Observational studies Prospective cohort studies (can be single group or single arm that used diagnostic intervention specified in question) Cross-sectional accuracy studies (if insufficient data from randomized controlled management trials or prospective management studies)	
What are the consequences of using CT scan venography to exclude recurrent DVT?	Patients with suspected recurrent DVT	Negative CT scan venography	Venography or VTE during additional testing or 3-6 mo follow-up if intervention shows no evidence of recurrence	FN/1,000 (eg, post-TP of a negative test) if management study Sensitivity if accuracy study Morbidity caused by test strategy	RCTs Observational studies Prospective cohort studies (can be single group or single arm that used diagnostic intervention specified in question) Cross-sectional accuracy studies (if insufficient data from randomized controlled management trials or prospective management studies)	

(Continued)

Table 1—Continued

Informal Question		PICO Question			Methodology
Informal Question	Population	Intervention	Comparator	Outcome	Methodology
What are the consequences of using contrast MR venography to diagnose recurrent DVT	Patients with suspected recurrent DVT	Intraluminal filling defect	Venography	FP/1,000 of positive (eg, post-TP of a management study Specificity if accuracy study Morbidity caused by test strategy	RCTs Observational studies Prospective cohort studies (can be single group or single arm that used diagnostic intervention specified in question) Cross-sectional accuracy studies (if insufficient data from randomized controlled management trials or prospective management studies)
What are the consequences of using contrast MR venography to exclude recurrent DVT?	Patients with suspected recurrent DVT	Negative MR venography	Venography or VTE during additional testing or 3-6 mo follow-up if intervention shows no evidence of recurrence	FN/1,000 (eg, post-TP of a negative test) if management study Sensitivity if accuracy study Morbidity caused by test strategy	RCTs Observational studies Prospective cohort studies (can be single group or single arm that used diagnostic intervention specified in question) Cross-sectional accuracy studies (if insufficient data from randomized controlled management trials or prospective management studies)
What are the consequences of using MR direct thrombus imaging to diagnose recurrent DVT?	Patients with suspected recurrent DVT	High signal intensity	Venography	FP/1,000 of positive (eg, post-TP of a management study Specificity if accuracy study Morbidity caused by test strategy	RCTs Observational studies Prospective cohort studies (can be single group or single arm that used diagnostic intervention specified in question) Cross-sectional accuracy studies (if insufficient data from randomized controlled management trials or prospective management studies)
What are the consequences of using MR direct thrombus imaging to exclude recurrent DVT?	Patients with suspected recurrent DVT	Negative MR direct thrombus imaging	Venography or VTE during additional testing or 3-6 mo follow-up if intervention shows no evidence of recurrence	FN/1,000 (eg, post-TP of a negative test) if management study Sensitivity if accuracy study Morbidity caused by test strategy	RCTs Observational studies Prospective cohort studies (can be single group or single arm that used diagnostic intervention specified in question) Cross-sectional accuracy studies (if insufficient data from randomized controlled management trials or prospective management studies)
What are the consequences of using venography to diagnose DVT during pregnancy	Patients with suspected recurrent DVT	Persistent intraluminal filling defect	Suspected DVT in pregnancy (Section 5.0)	FP/1,000 of positive (eg, post-TP of a positive test) Morbidity caused by test strategy Radiation exposure to the fetus (also teratogenicity, increase in the risk of childhood cancer, fetal loss)	RCTs Observational studies Prospective cohort studies (can be single group or single arm that used diagnostic intervention specified in question) Cross-sectional accuracy studies (if insufficient data from randomized controlled management trials or prospective management studies)

(Continued)

Table 1—Continued

Informal Question	PICO Question				Methodology
	Population	Intervention	Comparator	Outcome	
What are the consequences of using venography to rule out DVT during pregnancy?	Patients with suspected recurrent DVT	Negative venography	VTE during additional testing or 3-6 mo follow-up if intervention shows no evidence of DVT	FN/1,000 (eg, post-TP of a negative test) Morbidity caused by test strategy Radiation exposure to the fetus (also teratogenicity, increase in the risk of childhood cancer, fetal loss)	RCTs Observational studies Prospective cohort studies (can be single group or single arm that used diagnostic intervention specified in question) Cross-sectional accuracy studies (if insufficient data from randomized controlled management trials or prospective management studies)
What are the consequences of using CUS to diagnose proximal DVT during pregnancy?	Pregnant women with suspected DVT	Noncompressible venous segment from common femoral vein down to and including the trifurcation veins and/or absence of Doppler flow in the iliac vein In all patients If low pre-TP If moderate pre-TP If high pre-TP If positive highly sensitive DD If positive moderately sensitive (Simplified) DD If negative highly sensitive DD If negative moderately sensitive (Simplified) DD	Venography	FP/1,000 of positive (eg, post-TP of a positive test) if management study Specificity if accuracy study Morbidity caused by test strategy	RCTs Observational studies Prospective cohort studies (can be single group or single arm that used diagnostic intervention specified in question) Cross-sectional accuracy studies (if insufficient data from randomized controlled management trials or prospective management studies)
What are the consequences of using serial proximal CUS to exclude DVT during pregnancy, regardless of pre-TP?	Pregnant women with suspected DVT	Proximal CUS on presentation and if negative follow-up tests within 5-10 d	Venography or VTE during additional testing or 3-6 mo follow-up if intervention shows no evidence of DVT	FN/1,000 (eg, post-TP of a negative test) if management study Sensitivity if accuracy study Morbidity caused by test strategy	RCTs Observational studies Prospective cohort studies (can be single group or single arm that used diagnostic intervention specified in question) Cross-sectional accuracy studies (if insufficient data from randomized controlled management trials or prospective management studies)

(Continued)

Table 1—Continued

		PICO Question				
Informal Question	Population	Intervention	Comparator	Outcome	Methodology	
What are the consequences of using a negative proximal CUS and negative DD to exclude DVT during pregnancy?	Pregnant women with suspected DVT	Negative moderately sensitive (Simplified) plus negative proximal CUS at presentation OR Negative highly sensitive DD plus negative proximal CUS at presentation	Venography or VTE during additional testing or 3-6 mo follow-up if intervention shows no evidence of DVT	FN/1,000 (eg, post-TP of a negative test) if management study Sensitivity if accuracy study Morbidity caused by test strategy	RCTs Observational studies Prospective cohort studies (can be single group or single arm that used diagnostic intervention specified in question) Cross-sectional accuracy studies (if insufficient data from randomized controlled management trials or prospective management studies)	
What are the consequences of using pre-TP with a negative proximal CUS to exclude DVT during pregnancy?	Pregnant women with suspected DVT	Negative proximal CUS plus low/moderate/high pre-TP at presentation	Venography or VTE during additional testing or 3-6 mo follow-up if intervention shows no evidence of DVT	FN/1,000 (eg, post-TP of a negative test) if management study Sensitivity if accuracy study Morbidity caused by test strategy	RCTs Observational studies Prospective cohort studies (can be single group or single arm that used diagnostic intervention specified in question) Cross-sectional accuracy studies (if insufficient data from randomized controlled management trials or prospective management studies)	
What are the consequences of using serial proximal CUS to exclude DVT in patients with a low/moderate/high pre-TP during pregnancy?	Pregnant women with suspected DVT	Repeat proximal CUS (within approximately 1 wk)	Venography or VTE during additional testing or 3-6 mo follow-up if intervention shows no evidence of DVT	FN/1,000 (eg, post-TP of a negative test) if management study Sensitivity if accuracy study Morbidity caused by test strategy	RCTs Observational studies Prospective cohort studies (can be single group or single arm that used diagnostic intervention specified in question) Cross-sectional accuracy studies (if insufficient data from randomized controlled management trials or prospective management studies)	
What are the consequences of using serial proximal CUS to exclude DVT in patients with a positive DD during pregnancy?	Pregnant women with suspected DVT	Repeat proximal CUS (within approximately 1 wk)	Venography or VTE during additional testing or 3-6 mo follow-up if intervention shows no evidence of DVT	FN/1,000 (eg, post-TP of a negative test) if management study Sensitivity if accuracy study Morbidity caused by test strategy	RCTs Observational studies Prospective cohort studies (can be single group or single arm that used diagnostic intervention specified in question) Cross-sectional accuracy studies (if insufficient data from randomized controlled management trials or prospective management studies)	
Negative proximal CUS plus positive moderately sensitive (Simplified) or highly sensitive DD plus low pre-TP						
Negative proximal CUS plus positive moderately sensitive (Simplified) or highly sensitive DD plus moderate pre-TP						
Negative proximal CUS plus positive highly sensitive DD plus high pre-TP						

(Continued)

Table 1—Continued

Informal Question	PICO Question				Methodology
	Population	Intervention	Comparator	Outcome	
What are the consequences of using a negative DD to obviate the need for serial testing in patients with a negative proximal CUS and moderate or high pre-TP at presentation during pregnancy? Negative proximal CUS plus moderate pre-TP Negative proximal CUS plus high pre-TP	Pregnant women with suspected DVT	Negative highly sensitive DD or negative moderately sensitive (Simplified) DD	Venography or VTE during additional testing or 3-6 mo follow-up if intervention shows no evidence of DVT	FN/1,000 (eg, post-TP of a negative test) if management study Sensitivity if accuracy study Morbidity caused by test strategy	RCTs Observational studies Prospective cohort studies (can be single group or single arm that used diagnostic intervention specified in question) Cross-sectional accuracy studies (if insufficient data from randomized controlled management trials or prospective management studies)
What are the consequences of using pre-TP with a negative proximal CUS to exclude DVT?	Pregnant women with suspected DVT	Negative proximal CUS plus low/moderate/high pre-TP at presentation	Venography or VTE during additional testing or 3-6 mo follow-up if intervention shows no evidence of DVT	FN/1,000 (eg, post-TP of a negative test) if management study Sensitivity if accuracy study Morbidity caused by test strategy	RCTs Observational studies Prospective cohort studies (can be single group or single arm that used diagnostic intervention specified in question) Cross-sectional accuracy studies (if insufficient data from randomized controlled management trials or prospective management studies)
What are the consequences of using serial proximal CUS to exclude DVT in patients with a low/moderate/high pre-TP?	Pregnant women with suspected DVT	Repeat proximal CUS (within approximately 1 wk)	Venography or VTE during additional testing or 3-6 mo follow-up if intervention shows no evidence of DVT	FN/1,000 (eg, post-TP of a negative test) if management study Sensitivity if accuracy study Morbidity caused by test strategy	RCTs Observational studies Prospective cohort studies (can be single group or single arm that used diagnostic intervention specified in question) Cross-sectional accuracy studies (if insufficient data from randomized controlled management trials or prospective management studies)

(Continued)

Table 1—Continued

PICO Question					
Informal Question	Population	Intervention	Comparator	Outcome	
What are the consequences of whole-leg US to diagnose distal DVT during pregnancy	Pregnant women with suspected DVT	Noncompressible venous segment isolated to the calf veins (eg, posterior tibial, anterior tibial, and peroneal veins) In all patients If low pre-TP If moderate pre-TP If high pre-TP If positive highly sensitive DD If positive moderately sensitive (Simplified) DD If negative highly sensitive DD If negative moderately sensitive (Simplified) DD	Venography or serial proximal CUS during additional 3-6 mo if negative for proximal DVT	FP/1,000 of positive (eg, post-TP of a positive test) if management study Specificity if accuracy study Morbidity caused by test strategy	Methodology RCTs Observational studies Prospective cohort studies (can be single group or single arm that used diagnostic intervention specified in question) Cross-sectional accuracy studies (if insufficient data from randomized controlled management trials or prospective management studies)
What are the consequences of using a single whole-leg US to exclude DVT during pregnancy?	Pregnant women with suspected DVT	Negative single whole-leg US on day of presentation	Venography or VTE during additional testing or 3-6 mo follow-up if intervention shows no evidence of DVT	FN/1,000 (eg, post-TP of a negative test) if management study Sensitivity if accuracy study Morbidity caused by test strategy	RCTs Observational studies Prospective cohort studies (can be single group or single arm that used diagnostic intervention specified in question) Cross-sectional accuracy studies (if insufficient data from randomized controlled management trials or prospective management studies)
What are the consequences of using a highly sensitive DD as a stand-alone test to exclude DVT during pregnancy?	Pregnant women with suspected DVT	Negative highly sensitive DD on day of presentation	Venography or VTE during additional testing or 3-6 mo follow-up if intervention shows no evidence of DVT	Venography or VTE during additional testing or 3-6 mo follow-up if intervention shows no evidence of DVT	RCTs Observational studies Prospective cohort studies (can be single group or single arm that used diagnostic intervention specified in question) Cross-sectional accuracy studies (if insufficient data from randomized controlled management trials or prospective management studies)

(Continued)

Table 1—Continued

PICO Question				
Informal Question	Population	Intervention	Comparator	Outcome
What are the consequences of using a moderately sensitive (SimpliRED) DD as a stand-alone test to exclude DVT pregnancy?	Pregnant women with suspected DVT	Negative moderately sensitive (SimpliRED) DD on day of presentation	Venography or VTE during additional testing or 3-6 mo follow-up if intervention shows no evidence of DVT	Venography or VTE during additional testing or 3-6 mo follow-up if intervention shows no evidence of DVT
What are the consequences of using CT scan venography to diagnose DVT during pregnancy?	Pregnant women with suspected DVT	Intraluminal filling defect	Venography	<p>FP/1,000 of positive (eg, post-TP of a positive test) if management study</p> <p>Morbidity caused by test strategy</p> <p>Radiation exposure to the fetus (also teratogenicity, increase in the risk of childhood cancer, fetal loss)</p>
What are the consequences of using CT scan venography to exclude DVT during pregnancy?	Pregnant women with suspected DVT	Negative CT scan venography	Venography or VTE during additional testing or 3-6 mo follow-up if intervention shows no evidence of DVT	<p>FN/1,000 (eg, post-TP of a negative test) if management study</p> <p>Sensitivity if accuracy study</p> <p>Morbidity caused by test strategy</p> <p>Radiation exposure to the fetus (also teratogenicity, increase in the risk of childhood cancer, fetal loss)</p>
What are the consequences of using contrast MR venography to diagnose DVT during pregnancy?	Pregnant women with suspected DVT	Intraluminal filling defect	Venography	<p>FP/1,000 of positive (eg, post-TP of a positive test) if management study</p> <p>Morbidity caused by test strategy</p> <p>Teratogenicity, increase in the risk of childhood cancer, fetal loss</p>

(Continued)

Table 1—Continued

PICO Question		Comparator	Outcome	Methodology
Informal Question	Population	Intervention	Outcome	Methodology
What are the consequences of using MR venography to exclude DVT during pregnancy?	Pregnant women with suspected DVT	Negative MR venography	FN/1,000 (eg, post-TP of a negative test) if management study Sensitivity if accuracy study Morbidity caused by test strategy Teratogenicity, increase in the risk of childhood cancer, fetal loss	RCTs Observational studies Prospective cohort studies (can be single group or single arm that used diagnostic intervention specified in question) Cross-sectional accuracy studies (if insufficient data from randomized controlled management trials or prospective management studies)
What are the consequences of using MR direct thrombus imaging to diagnose DVT during pregnancy?	Pregnant women with suspected DVT	High signal intensity	FP/1,000 of positive (eg, post-TP of a positive test) if management study Specificity if accuracy study Morbidity caused by test strategy Teratogenicity, increase in the risk of childhood cancer, fetal loss	RCTs Observational studies Prospective cohort studies (can be single group or single arm that used diagnostic intervention specified in question) Cross-sectional accuracy studies (if insufficient data from randomized controlled management trials or prospective management studies)
What are the consequences of using MR direct thrombus imaging to exclude DVT during pregnancy?	Pregnant women with suspected DVT	Negative MR direct thrombus imaging	FN/1,000 (eg, post-TP of a negative test) if management study Specificity if accuracy study Morbidity caused by test strategy Teratogenicity, increase in the risk of childhood cancer, fetal loss	RCTs Observational studies Prospective cohort studies (can be single group or single arm that used diagnostic intervention specified in question) Cross-sectional accuracy studies (if insufficient data from randomized controlled management trials or prospective management studies)
What are the consequences of using venography to diagnose upper extremity DVT?	Patient with suspected upper extremity DVT	Intraluminal filling defect	Morbidity caused by test strategy Number of nonevaluable test results	RCTs Observational studies Prospective cohort studies (can be single group or single arm that used diagnostic intervention specified in question) Cross-sectional accuracy studies (if insufficient data from randomized controlled management trials or prospective management studies)
Suspected upper extremity DVT (Section 6.0)				
What are the consequences of using venography to diagnose upper extremity DVT?	Patient with suspected upper extremity DVT	Intraluminal filling defect	Morbidity caused by test strategy Number of nonevaluable test results	RCTs Observational studies Prospective cohort studies (can be single group or single arm that used diagnostic intervention specified in question) Cross-sectional accuracy studies (if insufficient data from randomized controlled management trials or prospective management studies)

(Continued)

Table 1—Continued

PICO Question				
Informal Question	Population	Intervention	Comparator	Outcome
What are the consequences of using venography to rule out upper extremity DVT?	Patients with suspected upper extremity DVT	Negative venography	VTE during additional testing or 3-6 mo follow-up if intervention shows no evidence of recurrence	FN/1,000 (eg, post-TP of a negative test) Morbidity caused by test strategy
What are the consequences of using CUS to diagnose upper extremity DVT?	Patients with suspected upper extremity DVT	Noncompressible venous segment or visualization of echogenic material (intraluminal thrombus)	Venography	FP/1,000 of positive (eg, post-TP of a positive test) if management study Specificity if accuracy study Morbidity caused by test strategy
What are the consequences of using a single CUS to exclude upper extremity DVT?	Patients with suspected upper extremity DVT	Negative CUS on presentation	Venography or VTE during additional testing or 3-6 mo follow-up if intervention shows no evidence of DVT	FN/1,000 (eg, post-TP of a negative test) if management study Sensitivity if accuracy study Morbidity caused by test strategy
What are the consequences of using serial CUS to exclude upper extremity DVT?	Patients with suspected upper extremity DVT	CUS on presentation and if negative follow-up tests within 5-10 d	Venography or VTE during additional testing or 3-6 mo follow-up if intervention shows no evidence of DVT	FN/1,000 (eg, post-TP of a negative test) if management study Sensitivity if accuracy study Morbidity caused by test strategy
What are the consequences of using Doppler US to diagnose upper extremity DVT?	Patients with suspected upper extremity DVT	Absent flow/absence of phasic flow	Venography	FP/1,000 of positive (eg, post-TP of a positive test) if management study Specificity if accuracy study Morbidity caused by test strategy

Methodology	Methodology
RCTs Observational studies Prospective cohort studies (can be single group or single arm that used diagnostic intervention specified in question) Cross-sectional accuracy studies (if insufficient data from randomized controlled management trials or prospective management studies)	RCTs Observational studies Prospective cohort studies (can be single group or single arm that used diagnostic intervention specified in question) Cross-sectional accuracy studies (if insufficient data from randomized controlled management trials or prospective management studies)
RCTs Observational studies Prospective cohort studies (can be single group or single arm that used diagnostic intervention specified in question) Cross-sectional accuracy studies (if insufficient data from randomized controlled management trials or prospective management studies)	RCTs Observational studies Prospective cohort studies (can be single group or single arm that used diagnostic intervention specified in question) Cross-sectional accuracy studies (if insufficient data from randomized controlled management trials or prospective management studies)
RCTs Observational studies Prospective cohort studies (can be single group or single arm that used diagnostic intervention specified in question) Cross-sectional accuracy studies (if insufficient data from randomized controlled management trials or prospective management studies)	RCTs Observational studies Prospective cohort studies (can be single group or single arm that used diagnostic intervention specified in question) Cross-sectional accuracy studies (if insufficient data from randomized controlled management trials or prospective management studies)
RCTs Observational studies Prospective cohort studies (can be single group or single arm that used diagnostic intervention specified in question) Cross-sectional accuracy studies (if insufficient data from randomized controlled management trials or prospective management studies)	RCTs Observational studies Prospective cohort studies (can be single group or single arm that used diagnostic intervention specified in question) Cross-sectional accuracy studies (if insufficient data from randomized controlled management trials or prospective management studies)

(Continued)

Table 1—Continued

PICO Question				
Informal Question	Population	Intervention	Comparator	Outcome
What are the consequences of using a single Doppler US to exclude upper extremity DVT?	Patients with suspected upper extremity DVT	Negative US on presentation	Venography or VTE during additional testing or 3-6 mo follow-up if intervention shows no evidence of DVT	<p>RCTs</p> <p>Observational studies</p> <p>Prospective cohort studies (can be single group or single arm that used diagnostic intervention specified in question)</p> <p>Cross-sectional accuracy studies (if insufficient data from randomized controlled management trials or prospective management studies)</p>
	Patients with suspected upper extremity DVT	Negative US on presentation and negative follow-up 5-10 d later	Venography or VTE during additional testing or 3-6 mo follow-up if intervention shows no evidence of DVT	<p>RCTs</p> <p>Observational studies</p> <p>Prospective cohort studies (can be single group or single arm that used diagnostic intervention specified in question)</p> <p>Cross-sectional accuracy studies (if insufficient data from randomized controlled management trials or prospective management studies)</p>
What are the consequences of using duplex US (compression plus Doppler flow) to diagnose upper extremity DVT?	Patients with suspected upper extremity DVT	Noncompressible segment or visualization of echogenic material (intraluminal thrombus) or absent flow/absence of phasic flow	Venography	<p>RCTs</p> <p>Observational studies</p> <p>Prospective cohort studies (can be single group or single arm that used diagnostic intervention specified in question)</p> <p>Cross-sectional accuracy studies (if insufficient data from randomized controlled management trials or prospective management studies)</p>
	Patients with suspected upper extremity DVT	Negative US on presentation	Venography or VTE during additional testing or 3-6 mo follow-up if intervention shows no evidence of DVT	<p>RCTs</p> <p>Observational studies</p> <p>Prospective cohort studies (can be single group or single arm that used diagnostic intervention specified in question)</p> <p>Cross-sectional accuracy studies (if insufficient data from randomized controlled management trials or prospective management studies)</p>
What are the consequences of using a single duplex US (compression plus Doppler flow) to exclude upper extremity DVT?	Patients with suspected upper extremity DVT	Negative US on presentation	Venography or VTE during additional testing or 3-6 mo follow-up if intervention shows no evidence of DVT	<p>RCTs</p> <p>Observational studies</p> <p>Prospective cohort studies (can be single group or single arm that used diagnostic intervention specified in question)</p> <p>Cross-sectional accuracy studies (if insufficient data from randomized controlled management trials or prospective management studies)</p>
	Patients with suspected upper extremity DVT	Negative US on presentation and negative follow-up 5-10 d later	Venography or VTE during additional testing or 3-6 mo follow-up if intervention shows no evidence of DVT	<p>RCTs</p> <p>Observational studies</p> <p>Prospective cohort studies (can be single group or single arm that used diagnostic intervention specified in question)</p> <p>Cross-sectional accuracy studies (if insufficient data from randomized controlled management trials or prospective management studies)</p>

(Continued)

Table 1—Continued

Informal Question		PICO Question			Methodology
	Population	Intervention	Comparator	Outcome	
What are the consequences of using a negative CUS and negative DD to exclude upper extremity DVT?	Patients with suspected upper extremity DVT	Negative moderately sensitive (SimpliRED) DD plus negative CUS at presentation or Negative highly sensitive DD plus negative CUS at presentation	Venography or VTE during additional testing or 3-6 mo follow-up if intervention shows no evidence of DVT	FN/1,000 (eg, post-TP of a negative test) if management study Sensitivity if accuracy study Morbidity caused by test strategy	RCTs Observational studies Prospective cohort studies (can be single group or single arm that used diagnostic intervention specified in question) Cross-sectional accuracy studies (if insufficient data from randomized controlled management trials or prospective management studies)
What are the consequences of using a negative Doppler US and negative DD to exclude upper extremity DVT?	Patients with suspected upper extremity DVT	Negative moderately sensitive (SimpliRED) DD plus negative doppler us at presentation or Negative highly sensitive DD plus negative Doppler US at presentation	Venography or VTE during additional testing or 3-6 mo follow-up if intervention shows no evidence of DVT	FN/1,000 (eg, post-TP of a negative test) if management study Sensitivity if accuracy study Morbidity caused by test strategy	RCTs Observational studies Prospective cohort studies (can be single group or single arm that used diagnostic intervention specified in question) Cross-sectional accuracy studies (if insufficient data from randomized controlled management trials or prospective management studies)
What are the consequences of using a negative duplex US and negative DD to exclude upper extremity DVT?	Patients with suspected upper extremity DVT	Negative moderately sensitive (SimpliRED) DD plus negative duplex US at presentation or Negative highly sensitive DD plus negative duplex US at presentation	Venography or VTE during additional testing or 3-6 mo follow-up if intervention shows no evidence of DVT	FN/1,000 (eg, post-TP of a negative test) if management study Sensitivity if accuracy study Morbidity caused by test strategy	RCTs Observational studies Prospective cohort studies (can be single group or single arm that used diagnostic intervention specified in question) Cross-sectional accuracy studies (if insufficient data from randomized controlled management trials or prospective management studies)
What are the consequences of using pre-TP with a negative CUS to exclude upper extremity DVT?	Patients with suspected upper extremity DVT	Negative CUS plus low/moderate/high pre-TP at presentation	Venography or VTE during additional testing or 3-6 mo follow-up if intervention shows no evidence of DVT	FN/1,000 (eg, post-TP of a negative test) if management study Sensitivity if accuracy study Morbidity caused by test strategy	RCTs Observational studies Prospective cohort studies (can be single group or single arm that used diagnostic intervention specified in question) Cross-sectional accuracy studies (if insufficient data from randomized controlled management trials or prospective management studies)

(Continued)

Table 1—Continued

PICO Question					
Informal Question	Population	Intervention	Comparator	Outcome	
What are the consequences of using pre-TP with a negative Doppler US to exclude upper extremity DVT?	Patients with suspected upper extremity DVT	Negative Doppler US plus low/moderate/high pre-TP at presentation	Venography or VTE during additional testing or 3-6 mo follow-up if intervention shows no evidence of DVT	FN/1,000 (eg, post-TP of a negative test) if management study Sensitivity if accuracy study Morbidity caused by test strategy	Methodology RCTs Observational studies Prospective cohort studies (can be single group or single arm that used diagnostic intervention specified in question) Cross-sectional accuracy studies (if insufficient data from randomized controlled management trials or prospective management studies)
What are the consequences of using pre-TP with a negative duplex US to exclude upper extremity DVT?	Patients with suspected upper extremity DVT	Negative duplex US plus low/moderate/high pre-TP at presentation	Venography or VTE during additional testing or 3-6 mo follow-up if intervention shows no evidence of DVT	FN/1,000 (eg, post-TP of a negative test) if management study Sensitivity if accuracy study Morbidity caused by test strategy	Methodology RCTs Observational studies Prospective cohort studies (can be single group or single arm that used diagnostic intervention specified in question) Cross-sectional accuracy studies (if insufficient data from randomized controlled management trials or prospective management studies)
What are the consequences of using serial CUS to exclude DVT in patients with a low/moderate/high pre-TP of upper extremity DVT?	Patients with suspected upper extremity DVT	Repeat CUS (within approximately 1 wk)	Venography or VTE during additional testing or 3-6 mo follow-up if intervention shows no evidence of DVT	FN/1,000 (eg, post-TP of a negative test) if management study Sensitivity if accuracy study Morbidity caused by test strategy	Methodology RCTs Observational studies Prospective cohort studies (can be single group or single arm that used diagnostic intervention specified in question) Cross-sectional accuracy studies (if insufficient data from randomized controlled management trials or prospective management studies)
What are the consequences of using serial Doppler US to exclude DVT in patients with a low/moderate/high pre-TP of upper extremity DVT?	Patients with suspected upper extremity DVT	Repeat Doppler US (within approximately 1 wk)	Venography or VTE during additional testing or 3-6 mo follow-up if intervention shows no evidence of DVT	FN/1,000 (eg, post-TP of a negative test) if management study Sensitivity if accuracy study Morbidity caused by test strategy	Methodology RCTs Observational studies Prospective cohort studies (can be single group or single arm that used diagnostic intervention specified in question) Cross-sectional accuracy studies (if insufficient data from randomized controlled management trials or prospective management studies)
What are the consequences of using serial duplex US to exclude DVT in patients with a low/moderate/high pre-TP of upper extremity DVT?	Patients with suspected upper extremity DVT	Repeat duplex US (within approximately 1 wk)	Venography or VTE during additional testing or 3-6 mo follow-up if intervention shows no evidence of DVT	FN/1,000 (eg, post-TP of a negative test) if management study Sensitivity if accuracy study Morbidity caused by test strategy	Methodology RCTs Observational studies Prospective cohort studies (can be single group or single arm that used diagnostic intervention specified in question) Cross-sectional accuracy studies (if insufficient data from randomized controlled management trials or prospective management studies)

(Continued)

Table 1—Continued

PICO Question				
Informal Question	Population	Intervention	Comparator	Outcome
What are the consequences of using serial CUS to exclude upper extremity DVT in patients with a positive DD? Negative CUS plus positive moderately (SimpliRED) or highly sensitive DD plus low pre-TP Negative CUS plus positive moderately sensitive (SimpliRED) or highly sensitive DD plus moderate pre-TP Negative CUS plus positive highly sensitive DD plus high pre-TP	Patients with suspected upper extremity DVT	Repeat CUS (within approximately 1 wk)	Venography or VTE during additional testing or 3-6 mo follow-up if intervention shows no evidence of DVT	FN/1,000 (eg, post-TP of a negative test) if management study Sensitivity if accuracy study Morbidity caused by test strategy RCTs Observational studies Prospective cohort studies (can be single group or single arm that used diagnostic intervention specified in question) Cross-sectional accuracy studies (if insufficient data from randomized controlled management trials or prospective management studies)
What are the consequences of using serial Doppler US to exclude upper extremity DVT in patients with a positive DD? Negative Doppler US plus positive moderately sensitive (SimpliRED) or highly sensitive DD plus pre-TP Negative Doppler US plus positive highly sensitive DD plus high pre-TP	Patients with suspected upper extremity DVT	Repeat Doppler US (within approximately 1 wk)	Venography or VTE during additional testing or 3-6 mo follow-up if intervention shows no evidence of DVT	FN/1,000 (eg, post-TP of a negative test) if management study Sensitivity if accuracy study Morbidity caused by test strategy RCTs Observational studies Prospective cohort studies (can be single group or single arm that used diagnostic intervention specified in question) Cross-sectional accuracy studies (if insufficient data from randomized controlled management trials or prospective management studies)

(Continued)

Table 1—Continued

Informal Question	PICO Question			
	Population	Intervention	Comparator	Outcome
What are the consequences of using serial duplex US to exclude upper extremity DVT in patients with a positive DD? Negative duplex US plus positive moderately sensitive (SimpliRED) or highly sensitive DD plus low pre-TP Negative duplex US plus positive moderately sensitive (SimpliRED) or highly sensitive DD plus moderate pre-TP Negative duplex US plus positive highly sensitive DD plus high pre-TP	Patients with suspected upper extremity DVT	Repeat duplex US (within approximately 1 wk)	Venography or VTE during additional testing or 3-6 mo follow-up if intervention shows no evidence of DVT	FN/1,000 (eg, post-TP of a negative test) if management study Sensitivity if accuracy study Morbidity caused by test strategy
What are the consequences of using a negative DD to obviate the need for serial testing in patients with suspected upper extremity DVT and a negative CUS and moderate or high pre-TP at presentation? Negative CUS plus low pre-TP Negative CUS plus low pre-TP Negative CUS plus high pre-TP	Patients with suspected upper extremity DVT	Negative highly sensitive DD or negative moderately sensitive (SimpliRED) DD	Venography or VTE during additional testing or 3-6 mo follow-up if intervention shows no evidence of DVT	RCTs Observational studies Prospective cohort studies (can be single group or single arm that used diagnostic intervention specified in question) Cross-sectional accuracy studies (if insufficient data from randomized controlled management trials or prospective management studies)

(Continued)

Table 1—Continued

Informal Question	PICO Question				Methodology
	Population	Intervention	Comparator	Outcome	
What are the consequences of using a negative DD to obviate the need for serial testing in patients with suspected upper extremity DVT and a negative Doppler US and moderate or high pre-TP at presentation? Negative Doppler US plus low pre-TP Negative Doppler US plus moderate pre-TP Negative Doppler US plus high pre-TP	Patients with suspected upper extremity DVT	Negative sensitive DD or negative moderately sensitive (Simplified) DD	Venography or VTE during additional testing or 3-6 mo follow-up if intervention shows no evidence of DVT	FN/1,000 (eg, post-TP of a negative test) if management study Sensitivity if accuracy study Morbidity caused by test strategy	RCTs Observational studies Prospective cohort studies (can be single group or single arm that used diagnostic intervention specified in question) Cross-sectional accuracy studies (if insufficient data from randomized controlled management trials or prospective management studies)
What are the consequences of using a negative DD to obviate the need for serial testing in patients with suspected upper extremity DVT and a negative duplex US and moderate or high pre-TP at presentation? Negative duplex US plus low pre-TP Negative duplex US plus high pre-TP	Patients with suspected upper extremity DVT	Negative highly sensitive DD or negative moderately sensitive (Simplified) DD	Venography or VTE during additional testing or 3-6 mo follow-up if intervention shows no evidence of DVT	FN/1,000 (eg, post-TP of a negative test) if management study Sensitivity if accuracy study Morbidity caused by test strategy	RCTs Observational studies Prospective cohort studies (can be single group or single arm that used diagnostic intervention specified in question) Cross-sectional accuracy studies (if insufficient data from randomized controlled management trials or prospective management studies)

(Continued)

Table 1—Continued

Informal Question	PICO Question				Methodology
	Population	Intervention	Comparator	Outcome	
What are the consequences of using a highly sensitive DD as a stand-alone test to exclude upper extremity DVT?	Patients with suspected upper extremity DVT	Negative highly sensitive DD on day of presentation	Venography or VTE during additional testing or 3-6 mo follow-up if intervention shows no evidence of DVT	FN/1,000 (eg, post-TP of a negative test) if management study Sensitivity if accuracy study Morbidity caused by test strategy	RCTs Observational studies Prospective cohort studies (can be single group or single arm that used diagnostic intervention specified in question) Cross-sectional accuracy studies (if insufficient data from randomized controlled management trials or prospective management studies)
What are the consequences of using a moderately sensitive (Simplified) DD as a stand-alone test to exclude upper extremity DVT?	Patients with suspected upper extremity DVT	Negative moderately sensitive (Simplified) DD on day of presentation	Venography or VTE during additional testing or 3-6 mo follow-up if intervention shows no evidence of DVT	FN/1,000 (eg, post-TP of a negative test) if management study Sensitivity if accuracy study Morbidity caused by test strategy	RCTs Observational studies Prospective cohort studies (can be single group or single arm that used diagnostic intervention specified in question) Cross-sectional accuracy studies (if insufficient data from randomized controlled management trials or prospective management studies)
What are the consequences of using CT scan venography to diagnose upper extremity DVT?	Patients with suspected upper extremity DVT	Intraluminal filling defect	Venography	FP/1,000 of positive (eg, post-TP of a positive test) if management study Specificity if accuracy study Morbidity caused by test strategy	RCTs Observational studies Prospective cohort studies (can be single group or single arm that used diagnostic intervention specified in question) Cross-sectional accuracy studies (if insufficient data from randomized controlled management trials or prospective management studies)
What are the consequences of using CT scan venography to exclude upper extremity DVT?	Patients with suspected upper extremity DVT	Negative CT scan venography	Venography or VTE during additional testing or 3-6 mo follow-up if intervention shows no evidence of DVT	FN/1,000 (eg, post-TP of a negative test) if management study Sensitivity if accuracy study Morbidity caused by test strategy	RCTs Observational studies Prospective cohort studies (can be single group or single arm that used diagnostic intervention specified in question) Cross-sectional accuracy studies (if insufficient data from randomized controlled management trials or prospective management studies)

(Continued)

Table 1—Continued

Informal Question	PICO Question				Methodology
	Population	Intervention	Comparator	Outcome	
What are the consequences of using contrast MR venography to diagnose upper extremity DVT?	Patients with suspected upper extremity DVT	Intraluminal filling defect	Venography	FP/1,000 of positive (eg, post-TP of a management study Specificity if accuracy study Morbidity caused by test strategy	RCTs Observational studies Prospective cohort studies (can be single group or single arm that used diagnostic intervention specified in question) Cross-sectional accuracy studies (if insufficient data from randomized controlled management trials or prospective management studies)
What are the consequences of using MR venography to exclude upper extremity DVT?	Patients with suspected upper extremity DVT	Negative MR venography	Venography or VTE during additional testing or 3-6 mo follow-up if intervention shows no evidence of DVT	FN/1,000 (eg, post-TP of a negative test) if management study Sensitivity if accuracy study Morbidity caused by test strategy	RCTs Observational studies Prospective cohort studies (can be single group or single arm that used diagnostic intervention specified in question) Cross-sectional accuracy studies (if insufficient data from randomized controlled management trials or prospective management studies)
What are the consequences of using MR direct thrombus imaging to diagnose upper extremity DVT?	Patients with suspected upper extremity DVT	High signal intensity	Venography	FP/1,000 of positive (eg, post-TP of a management study Specificity if accuracy study Morbidity caused by test strategy	RCTs Observational studies Prospective cohort studies (can be single group or single arm that used diagnostic intervention specified in question) Cross-sectional accuracy studies (if insufficient data from randomized controlled management trials or prospective management studies)

(Continued)

Table 1—Continued

Informal Question	PICO Question				Methodology
	Population	Intervention	Comparator	Outcome	
What are the consequences of using MR direct thrombus imaging to exclude upper extremity DVT?	Patients with suspected upper extremity DVT	Negative MR direct thrombus imaging	Venography or VTE during additional testing or 3-6 mo follow-up if intervention shows no evidence of DVT	FN/1,000 (eg, post-TP of a negative test) if accuracy study Sensitivity if accuracy study Morbidity caused by test strategy	RCTs Observational studies Prospective cohort studies (can be single group or single arm that used diagnostic intervention specified in question) Cross-sectional accuracy studies (if insufficient data from randomized controlled management trials or prospective management studies)

For Pre-TP use available model and specify. Management study is one in which patient is managed (or treated) according to test results. CUS = compression ultrasonography; DD = D-dimer; FN = false negative; FP = false positive; MR = magnetic resonance; RCT = randomized controlled trial; sensitive DD = D-dimer with sensitivity $\geq 95\%$ in general population of patients with suspected VTE; TP = test probability; US = ultrasound.

We have judged diagnostic strategies acceptable if we are confident that they meet all of the following conditions: (1) management studies have established that the probability of objective diagnosis of symptomatic VTE during 3 to 6 months of follow-up after initial classification as DVT negative is $\leq 2\%$; (2) modeling suggests a $< 0.1\%$ (one in 1,000) risk of fatal PE (to illustrate, the calculated risk is 0.065% for routine venography and 0.076% for routine serial proximal compression US [CUS]) and nonfatal PE of $< 0.5\%$ (five in 1,000) (to illustrate, the calculated risk is 0.31% for routine venography and 0.37% for routine serial proximal CUS); (3) modeling suggests a $< 0.1\%$ (one in 1,000) risk of fatal hemorrhage (to illustrate, the calculated risk is 0.071% for routine venography and 0.084% for routine serial CUS) and nonfatal intracranial hemorrhage of $\leq 0.035\%$ (0.35/1,000) (to illustrate, the calculated risk is 0.025% for routine venography and 0.03% for routine serial proximal CUS); and (4) modeling suggests a risk of death from PE or hemorrhage of $< 0.17\%$ (1.7/1,000) (to illustrate, the calculated risk is 0.137% for routine venography and 0.159% for routine serial proximal CUS). These thresholds are admittedly arbitrary; those who choose different threshold may reach different conclusions. In the accompanying evidence profiles, we have rated down the quality of evidence if the CI around the estimate of a false-negative result after initial diagnostic testing crosses our 2% threshold.

1.1 Implications of Values and Preferences in the Diagnostic Process

When evaluating alternative diagnostic strategies in patients with suspected DVT, harmful effects, cost, and patient preference (eg, test discomfort, inconvenience, and diagnostic uncertainty) need to be considered. Unless stated, the cost (eg, to the patient, a third-party payer, or society) associated with different diagnostic strategies did not influence our recommendations.

Harmful effects of a given diagnostic strategy include not only acute (eg, renal toxicity) and long-term (eg, cancer secondary to radiation exposure) complications but also indirect complications associated with the incorrect diagnosis (eg, bleeding) or exclusion (subsequent DVT and/or PE) of DVT. A systematic review of patient preferences suggests that the disutility (unpleasantness) associated with an episode of nonfatal VTE and major nonfatal bleeding are similar.³⁶ This assessment is also supported by the results of a subsequent survey of all panelists for these guidelines that rated values and preferences associated with different standardized clinical scenarios, including episodes of nonfatal VTE and nonfatal major bleeding, as well as the use of different anti-thrombotic therapies.³⁶ Therefore, on average, we assume that patients attach equal value to nonfatal VTE and nonfatal major bleeding events. However, we also took into account that values and preferences vary markedly between individual patients and that there is often appreciable uncertainty about the average patient values we used.

We generally recommend against invasive diagnostic strategies when a comparably accurate noninvasive alternative is available. This is because invasive tests are generally associated with greater patient discomfort, side effects (eg, reactions to contrast) and radiation exposure than noninvasive tests. However, we recommend invasive testing over noninvasive testing if the benefits of a more accurate diagnosis outweigh these disadvantages. Individual patient preferences relating to test discomfort and tolerance for diagnostic uncertainty influence this decision. We also acknowledge that access to types of diagnostic testing differs (eg, many centers do not perform ascending venography) and that it is appropriate for such factors to influence the choice of diagnostic testing.

In making recommendations, we have placed the burden of proof with those who would claim a benefit with a more complex, invasive, or expensive diagnostic strategy. In the absence of such

proof (eg, the strategy has not been assessed in management studies), we generally recommend against such strategies. When recommendations were considered controversial by the panel (Recommendation 3.1), the results of panel votes are presented, along with the recommendation.

2.0 VENOGRAPHY: REFERENCE STANDARD FOR DIAGNOSIS OF DVT

Contrast venography is the criterion standard (eg, the benchmark or best-performing test) for the diagnosis of DVT.^{13,37-39} In this technique, iodinated contrast is injected into a dorsal foot vein to outline the entire deep venous system of the lower extremity. DVT is diagnosed by the presence of a constant intraluminal filling defect that is present in more than one view; nonfilling of a venous segment despite repeated injection is suspicious, but not diagnostic, of DVT.⁴⁰ Tables S2 to S4 present methods, descriptive results, and evidence profiles for diagnostic studies assessing venography in patients with first suspected lower extremity DVT. Withholding anticoagulants in patients with suspected first DVT who have a technically adequate normal venogram is associated with a low frequency of symptomatic DVT or PE during 3 months of follow-up (1.2%; 95% CI, 0.2%-4.4%).¹³ This frequency of subsequent disease is the standard against which all tests or diagnostic strategies used to exclude DVT are typically judged.

Venography is expensive, not uniformly available, uncomfortable for patients, and contraindicated in patients with renal insufficiency and severe allergic reactions to contrast medium. In 5% of patients, the dorsal foot vein cannot be cannulated.⁴¹ Even when venography is performed by experienced radiologists, inadequate imaging is common; in up to 20% of venograms there is inadequate visualization of a venous segment.^{13,42-46} Further, venography can be difficult to interpret and the designation of “DVT present” or “DVT absent” is subject to a considerable degree of both intraobserver (κ values ranging from 0.56-0.95) and interobserver (κ values ranging from 0.47-0.92) variation.^{43,47-52} Adverse reactions to contrast media include dizziness and nausea (complicating between 1% and 4% of procedures^{53,54}), severe allergic reactions (in 0% [95% CI, 0%-2.4%]⁵⁴ to 0.4% [95% CI, 0.1%-0.4%]⁵³ of patients) and post-venography DVT (confirmed by repeat venography in between 0% [95% CI, 0%-13.3%]⁵⁵ to 2% [95% CI, 0%-12.6%]⁵³ of patients).

The above limitations make venography unsuitable for routine use in patients presenting with suspected DVT. Venography is now rarely used in clinical practice and many hospitals are unable to perform the procedure. However, venography can serve as a reference standard and be used when other tests are

unable to definitely establish or exclude the diagnosis of DVT.

3.0 DIAGNOSIS OF SUSPECTED FIRST LOWER EXTREMITY DVT

The limitations of contrast venography have led to the development of other testing strategies for the evaluation of patients with suspected DVT.

3.1 Alternatives to Venography for the Evaluation of Suspected First Lower Extremity DVT

3.1.1 Pretest Probability Assessment: Although the clinical diagnosis of DVT is nonspecific and individual clinical features are of little value in diagnosing DVT,⁵⁶ clinical prediction or pretest probability estimates (structured and based on specific criteria or unstructured and empirical) are able to stratify patients into groups according to their probability of DVT.⁵⁶ Several structured scoring systems have been developed^{10,31,32,56-60}; the most well studied is the Wells score.^{6,10,31,56} This rule incorporates signs, symptoms, and risk factors for VTE to categorize patients as having a low, moderate, or high probability of DVT,³¹ with a prevalence of DVT of 5.0% (95% CI, 4%-8%), 17% (95% CI, 13%-23%), and 53% (95% CI, 44%-61%), respectively.¹⁰ A modification of the Wells score stratifies patients as being likely (prevalence of DVT, 28%; 95% CI, 24%-32%) or unlikely (prevalence of DVT, 6%; 95% CI, 4%-8%) to have DVT.³² The Wells score has limitations. Interobserver reliability has not been widely evaluated, although one study confirmed its reproducibility when used by resident physicians.⁶¹ One study found that the model performed less well in a primary care setting.⁶²

3.1.2 D-Dimer: D-dimer, a degradation product of cross-linked fibrin, is typically elevated in patients with acute DVT. However, because D-dimer levels may also be increased in a variety of nonthrombotic disorders (eg, malignancy, disseminated intravascular coagulation, increasing age, infection, pregnancy, following surgery or trauma, inflammatory conditions, atrial fibrillation, and stroke), D-dimer is a sensitive but nonspecific marker for VTE. Consequently, although a positive result is not useful in confirming the diagnosis of DVT, a negative result can aid in the exclusion of this diagnosis. In hospitalized and other acutely ill patients commonly affected by the conditions listed above, D-dimer testing has less usefulness because of the high frequency of false-positive results. A wide variety of D-dimer assays are available. In a

meta-analysis of 217 studies, enzyme-linked immunofluorescence assays (sensitivity 96%; 95% CI, 89%-98%), microplate enzyme-linked immunosorbent assays (ELISAs) (sensitivity 94%; 95% CI, 86%-97%), and quantitative latex or immunoturbidimetric assays (sensitivity 93%; 95% CI, 89%-95%) were more sensitive for DVT than were the whole blood D-dimer assay (sensitivity 83%; 95% CI, 67%-93%) and latex semiquantitative assays (sensitivity 85%; 95% CI, 68%-93%).⁶³ Based on these data, ELISAs and enzyme-linked immunofluorescence assays, along with the latex immunoturbidimetric assays, are generally termed “highly sensitive,” whereas the whole blood D-dimer assay is considered “moderately sensitive.”¹⁰ Of these tests, the whole blood D-dimer assay had the highest specificity (71%; 95% CI, 57%-82% vs 46% [95% CI, 31%-61%] for enzyme-linked immunofluorescence assays; 53% [95% CI, 38%-68%] for microplate ELISAs, and 53% [95% CI, 46%-61%] for quantitative latex or immunoturbidimetric assays).⁶³

3.1.3 Venous US: Venous US is the most widely used imaging study for the diagnosis of DVT.⁶⁴ Proximal CUS assesses compressibility of the femoral and popliteal veins. The inability to fully collapse a venous segment under gentle US probe pressure is considered diagnostic of DVT. Although distal DVT may be present in patients with a normal proximal US, it is seldom if ever associated with important clinical sequelae (PE or postthrombotic syndrome). However, as distal DVT may propagate proximally and lead to PE, additional investigations, such as pretest probability assessment, D-dimer testing, or a second proximal CUS performed 5 to 7 days later (serial or repeat US), are needed to exclude distal DVT or, if distal DVT cannot be excluded, to detect early extension into the proximal veins.^{22,65,66} Whole-leg US assesses the deep veins of both the proximal leg and calf. This technique has been studied as a means of excluding DVT as a stand-alone test, eliminating the need for a return visit for serial US. As whole-leg US results in treatment of distal DVT that will not extend,^{67,68} it carries the risk of overtreatment.

3.1.4 CT Scan Venography: CT scan venography typically involves injection of contrast media into an arm vein followed by helical CT imaging timed to coincide with opacification of the deep veins of the legs to allow assessment of these veins for thrombus. It therefore shares the disadvantage with conventional contrast venography of requiring administration of IV contrast but does not require cannulation of a foot vein (although this technique can be used). CT scan venography can be combined with CT scan pulmonary angiography to provide imaging for both

suspected DVT and suspected PE. Most studies of CT scan venography have been done this way.

3.1.5 MRI: MRI can be applied using a variety of techniques. Some techniques visualize blood flow without the need for contrast agents because they rely on the intrinsic properties of flowing blood (time-of-flight or phase-contrast venography). However, the imaging of vascular structures is often improved by the use of contrast agents, such as in IV gadolinium. MR contrast agents can be either injected into a vein in the foot or into the arm with imaging timed for optimal imaging of lower limb veins. Alternatively, MR can identify DVT by direct thrombus imaging. This technique involves visualizing thrombus (high signal due to red cell methemoglobin in the clot) against a suppressed background. This technique has the advantages of being noninvasive and not requiring IV contrast agents. However, MRI is not routinely accessible for this purpose in most centers.

3.2 Evaluation of Diagnostic Strategies for Suspected First Lower Extremity DVT

Pretest probability assessment, D-dimer testing, and venous US have been extensively investigated and are widely used either alone or in combination in patients with a suspected first DVT. Evaluation of CT scan venography and MRI in this patient population has been limited to accuracy studies.

Details of management studies in patients with suspected first DVT that used pretest probability, D-dimer, and proximal CUS are summarized in Table 2 and Tables S5 to S16.^{10,16-19,21-23,25,30-32,41,60,62,63,65,69-86} Table 2 describes the consequences of using specific strategies in terms of the probability of VTE being diagnosed during clinical follow-up when a given diagnostic strategy suggests that DVT is not present.

As shown in Table 2 and Tables S5 to S16, the pretest assessment (ie, prevalence of DVT) has a significant effect on the usefulness of D-dimer and proximal US. Categorizing patients as having a low pretest probability for DVT eliminates the need for (1) radiologic imaging (eg, US) in those with a negative D-dimer, and (2) serial or repeat testing in those with a normal proximal US. Although most patients with a positive CUS have a proximal DVT, this is progressively less true as pretest probability declines. In a study of 529 symptomatic patients, the posttest probability of DVT in those with a positive CUS (as assessed by venography) was 100% in patients with a high pretest probability, 96% in those with a moderate pretest probability, and 63% in patients with a low pretest probability.⁶

Tables 3 and 4 and Tables S17 to S23 summarize the methodology and results of studies assessing whole-leg

Table 2—[Sections 3.1-3.5] Summary of Outcomes for Diagnostic Studies Assessing DD, Pre-TP, and Proximal US for the Diagnosis of Suspected First Lower Extremity DVT

Pre-TP	Diagnostic Strategy Used to Exclude DVT	No. of Studies ^a	Quality of Evidence	Number of Patients Subjected to Given Diagnostic Strategy → Number Considered Negative for DVT at Completion of Testing	Overall Prevalence in Population of Interest → Incidence of VTE During Follow-up ^b Among Those Judged to Have DVT Excluded by Specified Diagnostic Strategy (ie, Post-TP of Disease), % (95% CI)
Low	Moderately sensitive DD negative	1 ⁷⁰ Meta-analysis, 3 ^{10,70,74}	Moderate	206 → 177	2.4 → 0.6 (0.03-2.7) 0.9
	Highly sensitive DD negative	5 ^{16,18,25,81,82} Meta-analysis, 3 ^{10,70,74}	High	1,270 → 824	0.5 (0.07-1.1) 1.1 (0.9-1.5) 6.7 → 1.0 (0.5-1.7)
	US negative	4 ^{17,30,31,78} 2 ^{16,32}	High	944 → 855 765 → 198	0.5 Cardiac: 0.4 (0.2-0.8) or Triage: 0.9 (0.9-2.2) 7.1 → 0.9 (0.5-1.6) 5 → 0 (0-1.5)
Low/moderate or unlikely	Single proximal US negative	1 ⁶⁹	Moderate	852 → 500	9.6 → 1.4 (0.7-2.6)
	Moderately sensitive DD negative	1 ³²	Moderate	317 → 218	5.0 → 0.92 (0.2-2.9)
	DD (mixed) negative	1 ²¹	Moderate	749 → 481	N/A → 0.42 (0.04-1.5)
Moderate	Highly sensitive DD negative	Meta-analysis, 1 ⁷⁴	Moderate	0.4 (0.04-1.1)	
	Single proximal US negative	1 ³²	Moderate	284 → 272	5.6 → 1.5 (0.5-3.3)
	DD (mixed) positive → single proximal US negative	1 ³²	Moderate	317 → 85	5 → 0 (0-3.5)
Moderate	Moderately sensitive DD negative	Meta-analysis, 3 ^{10,70,74}	Moderate	4.4	3.5 (1.4-6.9) SimpliRED 4.9 (3.6-6.8) or Clearview Simplify: 5.2 (4.1-6.5) NPV: 99 (96-100); LR (negative) 0.05 (0.01-0.21); estimated post-test prevalence, 1 Cardiac: 1.7 (1.0-3.8) for point of care and Triage: 4.3 (2.0-9.7)
	Highly sensitive DD negative	3 ^{18,25,77} Meta-analysis, 2 ^{10,70}	Moderate	655 → 214	25.7 → 0.57 (0.02-2.2)
	Single proximal US negative	1 ⁷⁸	Low	144 → 114	21.5 → 0.9 (0.05-4.1)
Moderate	Single proximal US negative → DD (mixed) negative	2 ^{16,32}	High	675 → 325	22.4 → 0 (0-0.9)
	Serial proximal US negative	3 ^{17,31,80}	Moderate	N/A → 365	15.8 (Based on 2 out of 3 studies) → 1.1 (0.4-2.5) 0.6 (0.4-0.9)
	Highly sensitive DD positive → Single proximal US negative	Meta-analysis ⁸⁵ 1 ⁷⁷	Moderate	134 → 73	19.4 → 0 (0-4.0)
Moderate	Single proximal US negative → DD (mixed) positive → single proximal US negative	1 ¹⁶	Moderate	426 → 94	18.8 → 0 (0-3.1)

(Continued)

Table 2—Continued

Pre-TP	Diagnostic Strategy Used to Exclude DVT	No. of Studies ^a	Quality of Evidence	Number of Patients Subjected to Given Diagnostic Strategy → Number Considered Negative for DVT at Completion of Testing	Overall Prevalence in Population of Interest → Incidence of VTE During Follow-up ^b Among Those Judged to Have DVT Excluded by Specified Diagnostic Strategy (ie, Post-TP of Disease), % (95% CI)
Moderate/high or likely	Single proximal US negative → moderately sensitive DD negative	1 ³⁰	Moderate	531 → 148	58.8 → 0 (0-2.0)
	Single proximal US negative → DD (mixed) negative	1 ³²	Moderate	249 → 81	49.5 → 0 (0-3.6)
	Serial proximal US negative	1 ³²	Moderate	246 → 181	27.1 → 1.1 (0.2-3.4)
	Single proximal US negative → DD (mixed) positive → single proximal US negative	1 ³²	Moderate	249 → 97	28.5 → 0 (0-3.0)
	Single proximal US negative → moderately sensitive DD positive → single proximal US negative	1 ³⁰	Moderate not to use, low to use	531 → 83	58.9 → 3.6 (1.0-9.1)
	Moderately sensitive DD negative	Meta-analysis, 2 ^{10,74}	Moderate	19	21.4 (8.5-37.9)
	Highly sensitive DD negative	Meta-analysis, 3 ^{10,70,74}	Moderate	NPV: 92 (81-97) 6.4 (1.7-14.5)	Cardiac: 6.5 (3.8-13.7) or Triage: 15.3 (7.4-30.1)
	Highly sensitive DD negative → single proximal US negative	2 ^{18,25}	Low	350 → 59	53.4 → 1.7 (0-7.8)
	Serial proximal US negative	4 ^{18,78,80,81}	Moderate	291 → 221	36.4 → 0.9 (0.2-2.8)
	Single proximal US negative → highly sensitive DD positive → single proximal US negative	1 ²⁵	Low	279 → 36	59.5 → 2.8 (0.1-12.5)
Single proximal US negative → venogram negative	3 ^{17,23,31}	Low	168 → 43	78.0 → 0 (0-6.7)	

(Continued)

Table 2—Continued

Pre-TP	Diagnostic Strategy Used to Exclude DVT	No. of Studies ^a	Quality of Evidence	Number of Patients Subjected to Given Diagnostic Strategy → Number Considered Negative for DVT at Completion of Testing	Overall Prevalence in Population of Interest → Incidence of VTE During Follow-up ^b Among Those Judged to Have DVT Excluded by Specified Diagnostic Strategy (ie, Post-TPof Disease), % (95% CI)
Not specified	Highly sensitive DD negative	Meta-analysis, 5 ^{63,70,72,74}	Moderate		Highest sensitivity: 97 Sensitivity: 97.7 (96.1-99.0) and specificity: 45.7 (28.0-66.6)
	Single proximal US negative, except if high pre-TP then venography	1 ²³	Moderate	474 → 343	Sensitivity: 93-96 Sensitivity: up to 94 Highest sensitivity: 96 (91-100)
	Single proximal US negative → moderately sensitive DD –	1 ⁸⁰	High	470 → 309	Sensitivity: up to 94 Highest sensitivity: 96 (91-100)
	Single proximal US and moderately sensitive DD negative	1 ²²		1739 → 828	Sensitivity: 93-96 Sensitivity: up to 94 Highest sensitivity: 96 (91-100)
	Combined			2,209 → 1,137	25.3 → 2.6 (1.4-4.5)
	Single proximal US negative → sensitive DD negative	1 ⁷⁶	High	686 → 598	13.2 → 1.0 (0.3-2.5)
	Serial proximal US	3 ^{41,65,80}	High	2,662 → 2,071	24.4 → 0.7 (0.3-1.4)
	Single proximal US and moderately sensitive DD positive → single proximal US negative	Meta-analysis, 1 ⁸⁶	Moderate	1,739 → 520	22.1 → 0.8 (0.4-1.4) 39.1 → 0.2 (0.2-0.8)
	Single proximal US and moderately sensitive DD, if negative stop; if positive → single proximal US	1 ¹⁹	Moderate	1,045 → 828	20.9 → 1.0 (0.7-1.5) 0.6 (0.4-0.9)
	Single proximal US negative → highly sensitive DD positive → single proximal US negative	1 ⁷⁶	Moderate	946 → 83	24.4 → 2.1 (1.2-3.5)
	Highly sensitive DD positive → serial proximal US negative	2 ^{18,25}		1,065 → 494	23.3 → 1.1 (0.6-1.9)
	Combined (3 above)			2,011 → 577	28.3 → 2.4 (0.4-7.4)
	Single proximal US negative → moderately sensitive DD positive → venogram negative	1 ⁸⁰	Low	470 → 58	34.5 → 2.2 (1.3-3.7) 31.6 → 2.3 (1.3-3.5) 13.2 → 3.5 (0.6-10.5)

Consequences in terms of presenting with VTE during clinical follow-up when specified strategies are used to rule out suspected first lower extremity DVT. LR = likelihood ratio; N/A = not available; NPV = negative predictive value. See Table 1 legend for expansion of other abbreviations.

^aMeta-analyses and management studies are reported separately. All meta-analyses include both management and accuracy studies. Results of meta-analyses are reported separately for each meta-analysis. Where feasible, results of management studies are pooled.

^bDuration of follow-up usually 3 mo; occasionally 6 mo.

US for the diagnosis of first DVT.^{14,19-21,24,26-29,64,87-123} Although whole-leg US generates a larger number of false-negative results than venography for the diagnosis of isolated calf vein thrombosis, almost all positive results will be true positives. Pooling data from 34 studies comparing US with venography for calf-vein DVT in symptomatic patients yielded a specificity of 96.0% (95% CI, 95.2%-96.8%).⁸⁷⁻¹²² Eight management studies have assessed the safety of withholding anticoagulants based a negative whole-leg US.^{19-21,24,26-29} The results of seven of these studies were pooled in a recent meta-analysis¹²³ that found that the 3-month rate of VTE after a single negative whole-leg US was 0.57% (95% CI, 0.25%-0.89%) (Table 3, Table S19).

Individual patient data from two studies were combined in order to ascertain the incidence rate of VTE following a negative whole-leg US in patients with varying pretest probabilities for DVT based on the three-category Wells score^{27,28,123} (Table S22). The 3-month incidence of VTE was 0.3% (95% CI, 0%-0.7%) for low, 0.8% (0%-1.8%) for moderate, and 2.5% (0%-7.11%) for patients with high pretest probability.

In an RCT not included in the meta-analysis, patients with either an abnormal sensitive D-dimer or a score corresponding to “DVT likely” using the Wells two-level prediction rule were randomized to either serial proximal CUS or whole-leg US (Table 3, Table S23). The 3-month rate of VTE was 2.0% (95% CI, 0.6%-5.1%) in the group with negative serial proximal US (n = 198) and 1.2% (95% CI, 0.2%-4.3%) in the negative whole-leg US group (n = 165), (absolute difference in frequency of VTE during follow-up: 0.8%; 95% CI, -1.8 to 3.4).²¹

A subsequent management study of 431 patients explored the net effect of using whole-leg US vs serial proximal US (Tables 4, 5).¹²⁴ Patients with no proximal

DVT and either an abnormal sensitive D-dimer or a score corresponding to “DVT likely” using the Wells two-level prediction rule were managed with serial proximal US. Whole-leg US was also performed, but results were blinded and not used for management. Sixty-five patients (15.3%; 95% CI, 12.0%-18.8%) were found to have DVT isolated to the calf. Of the 64 who completed follow-up, two patients with isolated calf DVT experienced extension into the proximal system, which was detected on serial proximal US.

Tables S24 to S26 present the results of our modeling and decision analysis. In all tables, the denominator is 1,000 patients managed according to each diagnostic strategy; Table S24 presents the number of expected clinical events, and Table S25 presents the incremental number of events compared with a strategy of serial proximal US. Table S26 contains the number of tests performed with each strategy and the incremental number of tests compared with a serial proximal US strategy. The latter was used for comparative purposes as it is one of the strategies least likely to produce false-negative results.

Although a whole-leg US strategy reduces the number of US sessions compared with serial proximal US, routine anticoagulation of patients with isolated calf DVT will result in a larger number receiving treatment and an increase in bleeding complications. As only a relatively small portion of isolated calf DVT would propagate or embolize without treatment, some patients undergoing whole-leg US will receive anticoagulation for a disease with a benign prognosis if left untreated (Kearon et al).¹¹ The absence of a clear safety advantage for the whole-leg US strategy is demonstrated in Table S24, wherein the point estimate for the risk of fatal PE with a serial proximal US strategy is no higher than one involving whole-leg US. Guidelines for determining which patients are likely to most benefit from anticoagulant

Table 3—[Sections 3.2-3.5] Summary of Findings for Diagnostic Studies Evaluating Whole-Leg US in First Suspected Lower Extremity DVT: Prospective Cohort Management Studies

Diagnostic Strategy Used to Exclude DVT	No. of Participants (Studies) ^a	Outcome	Incidence of VTE During Follow-up in Those Judged to Have DVT Excluded (ie, Post-TP of DVT), % (95% CI)	Quality of Evidence
Single negative whole-leg US	4,731 (7) ^{72,114-119}	VTE during clinical follow-up (3 mo)	0.57 (0.25-0.89)	Moderate ^b

Consequences in terms of presenting with VTE during clinical follow-up when a single whole-leg US is used to rule out suspected first lower extremity DVT. GRADE Working Group grades of evidence: High quality: Further research is very unlikely to change our confidence in the estimate of effect. Moderate quality: Further research is likely to have an important impact on our confidence in the estimate of effect and may change the estimate. Low quality: Further research is very likely to have an important impact on our confidence in the estimate of effect and is likely to change the estimate. GRADE = Grades of Recommendation, Assessment, Development, and Evaluation; See Table 1 legend for expansion of other abbreviations.

^aIncludes six management studies and one arm from an RCT.

^bPooled management studies are of high methodologic quality and results are highly concordant. Moderate quality due to only one RCT among the analyzed studies.

Table 4—[Sections 3.2-3.5] Summary of Findings for Diagnostic Studies Evaluating Whole-Leg US in First Suspected Lower Extremity DVT: Randomized Trial (Single Whole-Leg US vs Serial Proximal US and DD)¹⁹

Outcomes	Illustrative Comparative Risks (95% CI)		Relative Effect (95% CI)	No. of Participants (Studies)	Quality of the Evidence (GRADE)	Comments
	Assumed Risk, Proximal US and DD	Corresponding Risk, Single Whole-Leg US				
VTE follow-up: mean, 3 mo	9 per 1,000	12 per 1,000 (0-16)	1.3 (0-1.8)	1,564 (1)	High ^a	Whole-leg US and the serial US/DD arms met predefined criteria for equivalence

Single whole-leg US compared with serial proximal US and DD for patients with suspected DVT.¹⁹ Patient or population: Patients with suspected DVT. Intervention: Single whole-leg US. Comparison: Serial proximal US (if moderately sensitive DD positive) or single proximal US (if moderately sensitive DD negative). GRADE Working Group grades of evidence: High quality: Further research is very unlikely to change our confidence in the estimate of effect. Moderate quality: Further research is likely to have an important impact on our confidence in the estimate of effect and may change the estimate. Low quality: Further research is very likely to have an important impact on our confidence in the estimate of effect and is likely to change the estimate. See Table 1 and 3 legends for expansion of abbreviations.

^aTrial was RCT without significant methodologic limitations.

therapy when isolated distal DVT is detected by whole-leg US (vs. surveillance to rule detect extension) are found in the article by Kearon et al¹¹ in this supplement.

Strategies involving CT scan venography and MRI were not included in the decision analysis. The methodology of a meta-analysis of CT scan diagnostic accuracy,¹²⁵ along with individual accuracy studies,¹²⁶⁻¹⁴³ is summarized in Table S27 (Recommendations 3.2-3.6). Most of the studies were of patients with suspected PE rather than suspected DVT. Only one compared CT scan venography with contrast venography;¹⁴³ the remainder compared CT scan venography to US.¹²⁶⁻¹⁴² The results of the meta-analysis¹²⁵ and five primary studies that were not included in the meta-analysis (mostly because they were subsequently published)^{126-129,133} are described in Tables S28 and S29, with the Summary of Findings in Table 6.¹⁴⁴⁻¹⁴⁶

All the studies reported results as sensitivity and specificity, rather than the frequency of VTE during follow-up in patients who had normal test results. The meta-analysis reported summary estimates of sensitivity and specificity despite evidence of heterogeneity between the individual studies.¹²⁵ Causes of heterogeneity were not formally explored. In the meta-analysis, the summary estimate of sensitivity was 95.2% (95% CI, 93.6%-96.5%), whereas the range in individual studies was from 93% to 100%. The summary estimate of specificity was 95.9% (95% CI, 93.0%-97.8%), whereas the range in individual studies was from 71% to 100%. Sensitivity was lower in the five studies not included in the meta-analysis. Across all studies, the range for sensitivity was 59% to 100%, whereas the range for specificity remains 71% to 100%.

The quality of the evidence for CT scan venography is low (Table 6, Tables S27, S28, and S30)

Table 5—[Section 3.2-3.5] Summary of Findings for Diagnostic Studies Evaluating Whole-Leg US in First Suspected Lower Extremity DVT: Randomized Trial (Single Whole-Leg US vs Serial Proximal US and DD in High-Risk Patients)²¹

Outcomes	Illustrative Comparative Risks (95% CI)		Relative Effect	No. of Participants (Studies)	Quality of the Evidence (GRADE)	Comments
	Assumed Risk, Serial Proximal US	Corresponding Risk, Single Whole-Leg US				
VTE follow-up: mean, 3 mo	20 per 1,000 (6-51)	12 per 1,000 (2-43)	0.6	521 (1)	High ^a	Reported $P = .69$ for difference in VTE events between strategies. Absolute difference, 0.8% (95% CI, -1.8 to -3.4)

Single whole-leg US compared with serial proximal US and DD for high-risk patients with suspected DVT.²¹ Patient or population: High-risk patients with suspected DVT. Settings: Symptomatic patients with likely Wells score or positive highly sensitive DD (Tina-quant). Intervention: Single whole-leg CUS. Comparison: Serial proximal CUS. GRADE Working Group grades of evidence: High quality: Further research is very unlikely to change our confidence in the estimate of effect. Moderate quality: Further research is likely to have an important impact on our confidence in the estimate of effect and may change the estimate. Low quality: Further research is very likely to have an important impact on our confidence in the estimate of effect and is likely to change the estimate. See Table 1 and 3 legends for expansion of abbreviations.

^aTrial was RCT without significant methodologic limitations.

Table 6—[Sections 3.2-3.6] Summary of Findings of Diagnostic Studies Evaluating CT Scan Venography, MR Venography, and MR Direct Thrombus Imaging in Patients with Suspected First Lower Extremity DVT: Accuracy Studies

Technique	Population and Reference Standard	Number of Studies	Quality of Evidence	Illustrative Comparative Numbers: Effect/1,000 ^a			
				True Positives (Correctly Classified as Having DVT)	True Negatives (Correctly Classified as Not Having DVT)	False Positives (Incorrectly Classified as Having DVT)	False Negatives (Incorrectly Classified as Not Having DVT)
CT scan venography ^b	Population: predominantly suspected PE	Meta-analysis of 13 plus 5 additional primary studies ^{125-129,133}	Low ^c	Prevalence 5%, 48	Prevalence 5%, 904	Prevalence 5%, 46	Prevalence 5%, 2
	Reference standard: predominantly US			Prevalence 17%, 163	Prevalence 17%, 790	Prevalence 17%, 40	Prevalence 17%, 7
MR venography ^d	Population: predominantly suspected DVT	Meta-analysis of 13 plus 1 additional primary studie ^{141,145}	Low ^e	Prevalence 5%, 46	Prevalence 5%, 901	Prevalence 5%, 49	Prevalence 5%, 4
	Reference standard: predominantly contrast venography			Prevalence 17%, 158	Prevalence 17%, 787	Prevalence 17%, 43	Prevalence 17%, 14
MR direct thrombus imaging ^f	Population: suspected DVT	1 Primary study ¹⁴⁶	Low ^g	Prevalence 5%, 47	Prevalence 5%, 874	Prevalence 5%, 76	Prevalence 5%, 3
	Reference standard: contrast venography			Prevalence 17%, 160	Prevalence 17%, 764	Prevalence 17%, 66	Prevalence 17%, 10
				Prevalence 53%, 498	Prevalence 53%, 432	Prevalence 53%, 38	Prevalence 53%, 32

GRADE Working Group grades of evidence: High quality: Further research is very unlikely to change our confidence in the estimate of effect. Moderate quality: Further research is likely to have an important impact on our confidence in the estimate of effect and may change the estimate. Low quality: Further research is very likely to have an important impact on our confidence in the estimate of effect and is likely to change the estimate. PE = pulmonary embolism. See Table 1 and 3 legends for expansion of other abbreviation.

^aPrevalences for high (53%), moderate (17%), and low (5%) taken from Wells et al.¹⁰
^bBased on a combined specificity of 95.2% (95% CI, 93.6%-96.5%) and sensitivity of 95.9% (95% CI, 93.0%-97.8%).
^cSerious limitations (in adequate reference standard), moderate inconsistency (significant heterogeneity between studies), serious indirectness (most studies were in suspected PE, few in suspected DVT; no management studies), and moderate imprecision (reported sensitivities range from 93%-100%; reported specificities range from 59%-100%).
^dBased on a combined specificity of 94.8% (95% CI, 92.6%-96.5%) and sensitivity of 91.5% (95% CI, 87.5%-94.5%).
^eNo major limitations, moderate inconsistency (significant heterogeneity between studies), moderate indirectness (no management studies), and serious imprecision (reported specificities range from 43%-100%, reported sensitivities range from 0-100%).
^fBased on a specificity of 92% (95% CI, 80%-98%) and sensitivity of 94.9% (95% CI, 84%-97%).
^gNo significant limitations, only single study, and moderate indirectness (management studies).

because studies generally used an inadequate reference standard, there was marked unexplained heterogeneity between studies, most studies were in patients with suspected PE rather than DVT, and there are no management studies to determine the consequences of using CT scan venography in practice. In summary, there is currently insufficient evidence to draw reliable conclusions about the consequences of using CT scan venography to diagnose or exclude suspected first lower extremity DVT.

Tables S31 and S32 summarize the methodology of a meta-analysis of 14 studies¹⁴⁴ and individual accuracy studies¹⁴⁵⁻¹⁵⁹ of MR diagnostic accuracy. Most of the studies in the meta-analysis were of MR venography (n = 13), but one study evaluated MR direct thrombus imaging.¹⁴⁶ The meta-analysis included all but one of the accuracy studies of MR venography.¹⁴⁵ The results of the meta-analysis and the additional primary study are described in Tables S33 and S34, with the Summary of Findings in Table 6. All the studies reported results as sensitivity and specificity rather than rates for VTE during follow-up in patients with negative test results.

The meta-analysis reported summary estimates of sensitivity and specificity despite evidence of heterogeneity between the individual studies.¹⁴⁴ The causes of heterogeneity were not formally explored. It also included the study of MR direct thrombus imaging.¹⁴⁶ In the meta-analysis, the summary estimate of sensitivity was 91.5% (95% CI, 87.5-94.5), whereas the range in individual studies was from 0% to 100%. The summary estimate of specificity was 94.8% (95% CI, 92.6%-96.5%), whereas the range in individual studies was from 43% to 100%. The additional study reported a sensitivity of 100% and a specificity of 78%.¹⁴⁵

As outlined in Table 6 and Tables S31 and S32 the quality of the evidence for MR venography is low. There was marked unexplained heterogeneity between studies and there were no management studies to determine the consequences of using MR venography in practice. In summary, MR venography may have similar diagnostic accuracy to US for patients with suspected DVT. However, as the evidence consists of diagnostic accuracy studies, the consequences of basing treatment decisions on the results of MR venography are not clear.

The methodology and results of the single study examining the accuracy of MR direct thrombus imaging¹⁴⁶ are described in Tables S35 to S37 and Table 6 (Summary of Findings, Recommendations 3.2-3.6). The study evaluated diagnostic accuracy compared with a reference standard of contrast venography in patients with suspected DVT. Sensitivity was 94% (95% CI, 84%-97%), and specificity was 92% (95% CI, 80%-98%). As outlined in Tables S35 and

S37 and Table 6, the evidence is of low quality, with only an accuracy study and no management studies to determine the consequences of using MR direct thrombus imaging in practice. In summary, MR direct thrombus imaging may have similar diagnostic accuracy to US for patients with suspected DVT, but the consequences of basing treatment decisions on the results of MR direct thrombus imaging are not clear.

As outlined above, patients who have had DVT excluded by diagnostic testing still have a small possibility of having thrombosis that could progress. Therefore, once testing has ruled out DVT, we recommend clinical follow-up, by which we mean that patients are aware of the need for further assessment if symptoms worsen or fail to resolve or if they develop symptoms suggestive of PE and there is a means to see and investigate patients promptly. It is also anticipated that patients with marked symptoms who have had DVT excluded will undergo assessment to identify an alternative diagnosis.

Recommendations (see Figs 1-5)

One approach to the evaluation of suspected first DVT is to begin by applying a pretest probability assessment to estimate the probability of DVT based on history and physical examination. We offer sets of recommendations both with and without their use.

3.1. In patients with a suspected first lower extremity DVT, we suggest that the choice of diagnostic tests process should be guided by the clinical assessment of pretest probability, rather than by performing the same diagnostic tests in all patients (Grade 2B).

Note: In considering this recommendation, five panelists voted for a strong recommendation and four voted for a weak recommendation (one declined to vote and two did not participate). According to predetermined criteria, this resulted in weak recommendation.

Testing Using Risk Stratification

3.2. In patients with a low pretest probability of first lower extremity DVT (see Fig 1), we recommend one of the following initial tests: (i) a moderately sensitive D-dimer, (ii) a highly sensitive d-dimer, or (iii) CUS of the proximal veins rather than (i) no diagnostic testing (Grade 1B for all comparisons), (ii) venography (Grade 1B for all comparisons), or (iii) whole-leg US (Grade 2B for all comparisons). We suggest initial use of a moderately sensitive (Grade 2C) or highly sensitive (Grade 2B) D-dimer rather than proximal CUS.

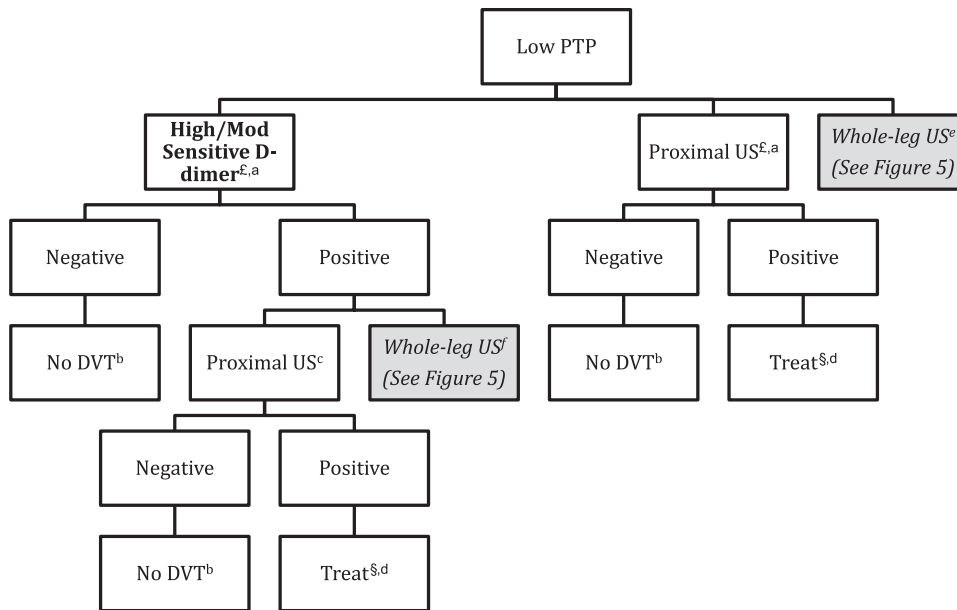


FIGURE 1. [Section 3.2] Recommendations for evaluation of suspected first lower extremity DVT: patients with low pretest probability (PTP) for DVT. Where there are preferred strategies, these are indicated by boldface print; less preferred strategies are indicated by italicizing/shading. Venography is not generally indicated in the figure, as it is not routinely used. §See Kearon et al.¹¹ £Beginning with moderately sensitive D-dimer (Grade 2C) or highly sensitive D-dimer (Grade 2B) is suggested over beginning with US. ^aGrade 1B vs no testing and vs venography; Grade 2B vs whole-leg US. ^bGrade 1B vs further testing. ^cGrade 1B vs venography; Grade 2C vs whole-leg US. ^dGrade 2C for treating DVT vs confirmatory venography. ^eGrade 2B for high/moderate sensitivity D-dimer or proximal US over whole-leg US. ^fGrade 2C for proximal US over whole-leg US. PTP = pretest probability; US = ultrasound.

Remarks: The choice between a moderately sensitive D-dimer test, a highly sensitive D-dimer test, or proximal CUS as the initial test will depend on local availability, access to testing, costs of testing, and the probability of obtaining a negative D-dimer result if DVT is not present. Initial testing with US would be preferred if the patient has a comorbid condition associated with elevated D-dimer levels and is likely to have a positive D-dimer result, even if DVT is absent. In patients with suspected first lower extremity DVT in whom US is impractical (eg, when leg casting or excessive subcutaneous tissue or fluid prevent adequate assessment of compressibility) or nondiagnostic we suggest CT scan venography, MR venography, or MR direct thrombus imaging could be used as an alternative to venography.

If the D-dimer is negative (see Fig 1), we recommend no further testing over further investigation with (i) proximal CUS, (ii) whole-leg US, or (iii) venography (Grade 1B for all comparisons). If the proximal CUS is negative, we recommend no further testing compared with (i) repeat proximal CUS after 1 week, (ii) whole-leg US, or (iii) venography (Grade 1B for all comparisons).

If the D-dimer is positive (see Fig 1), we suggest further testing with CUS of the proximal veins

rather than (i) whole-leg US (Grade 2C) or (ii) venography (Grade 1B). If CUS of the proximal veins is positive, we suggest treating for DVT and performing no further testing over performing confirmatory venography (Grade 2C).

Remarks: In circumstances when high-quality venography is available, patients who are not averse to the discomfort of venography, are less concerned about the complications of venography, and place a high value on avoiding treatment of false-positive results are likely to choose confirmatory venography if findings for DVT are less certain (eg, a short segment of venous noncompressibility).

3.3. In patients with a moderate pretest probability of first lower extremity DVT (see Fig 2), we recommend one of the following initial tests: (i) a highly sensitive D-dimer, or (ii) proximal CUS, or (iii) whole-leg US, rather than (i) no testing (Grade 1B for all comparisons) or (ii) venography (Grade 1B for all comparisons). We suggest initial use of a highly sensitive D-dimer rather than US (Grade 2C).

Remarks: The choice between a highly sensitive D-dimer test or US as the initial test will depend on local availability, access to testing, costs of testing,

(Grade 1B for all comparisons). **If proximal CUS is positive, we recommend treating for DVT rather than confirmatory venography** (Grade 1B). **If isolated distal DVT is detected on whole-leg US, we suggest serial testing to rule out proximal extension over treatment** (Grade 2C).

Remarks: Patients with abnormal isolated distal US findings on whole-leg US who place a high value on avoiding the inconvenience of repeat testing and a low value on avoiding treatment of false-positive results are likely to choose treatment over repeat US. Patients with severe symptoms and risk factors for extension as outlined in Kearon et al¹¹ are more likely to benefit from treatment over repeat US.

3.4. In patients with a high pretest probability of first lower extremity DVT (see Fig 3), we recommend either (i) proximal CUS or (ii) whole-leg US over no testing (Grade 1B for all comparisons) **or venography** (Grade 1B for all comparisons).

Remarks: Whole-leg US may be preferred to proximal CUS in patients unable to return for serial testing and those with severe symptoms consistent with calf DVT. In patients with extensive unexplained leg

swelling, if there is no DVT on proximal CUS or whole-leg US and D-dimer testing has not been performed or is positive, the iliac veins should be imaged to exclude isolated iliac DVT. In patients with suspected first lower extremity DVT in whom US is impractical (eg, when leg casting or excessive subcutaneous tissue or fluid prevent adequate assessment of compressibility) or nondiagnostic, we suggest CT scan venography, MR venography, or MR direct thrombus imaging could be used as an alternative to venography.

If proximal CUS or whole-leg US is positive for DVT (see Fig 3), we recommend treatment rather than confirmatory venography (Grade 1B).

In patients with a negative proximal CUS (see Fig 3), we recommend additional testing with a highly sensitive D-dimer or whole-leg US or repeat proximal CUS in 1 week over no further testing (Grade 1B for all comparisons) **or venography** (Grade 2B for all comparisons). **We recommend that patients with a single negative proximal CUS and positive D-dimer undergo whole-leg US or repeat proximal CUS in 1 week over no further testing** (Grade 1B) **or venography** (Grade 2B). **In patients with negative serial**

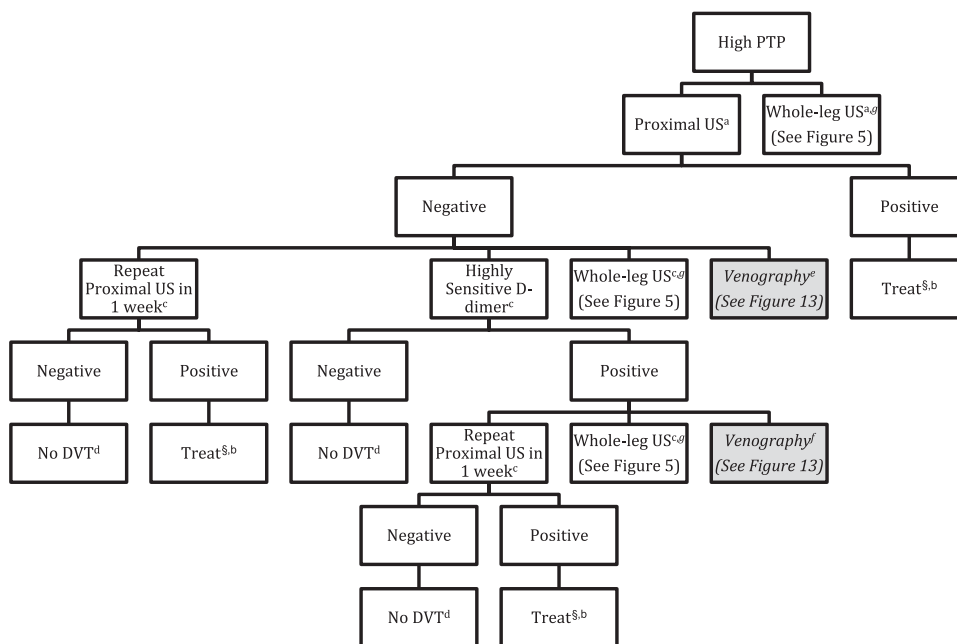


FIGURE 3. [Section 3.4] Recommendations for evaluation of suspected first lower extremity DVT: patients with high pretest probability (PTP) for DVT. Where there are preferred strategies, these are indicated by boldface print; less preferred strategies are indicated by italicizing/shading. Venography is not generally indicated in the figure, as it is not routinely used. ^aGrade 1B vs no testing and vs venography. ^bGrade 1B for treating DVT vs confirmatory venography. ^cGrade 1B vs no further testing; Grade 2B vs venography. ^dGrade 1B vs further testing. ^eGrade 2B for repeat proximal US, highly sensitive D-dimer or whole-leg US over venography. ^fGrade 2B for repeat proximal US over venography. ^gGrade 2B for no further testing over venography if whole-leg US is negative (see also Figure 5). See Figure 1 legend for expansion of abbreviation.

proximal CUS, a negative single proximal CUS and negative highly sensitive D-dimer, or a negative whole-leg US, we recommend no further testing over venography or additional US (Grade 1B for negative serial proximal CUS and for negative single proximal CUS and highly sensitive D-dimer; Grade 2B for negative whole-leg US).

We recommend that in patients with high pre-test probability (see Fig 3), moderately or highly sensitive D-dimer assays should not be used as stand-alone tests to rule out DVT (Grade 1B).

3.5. If risk stratification is not performed in patients with suspected first lower extremity DVT (see Fig 4), we recommend one of the following initial tests: (i) proximal CUS or (ii) whole-leg US, rather than (i) no testing (Grade 1B), (ii) venography (Grade 1B), or D-dimer testing (Grade 2B).

Remarks: Whole-leg US may be preferred to proximal CUS in patients unable to return for serial testing and those with severe symptoms consistent with calf DVT or risk factors for extension of distal DVT. In

patients with suspected first lower extremity DVT in whom US is impractical (eg, when leg casting or excessive subcutaneous tissue or fluid prevent adequate assessment of compressibility) or nondiagnostic, we suggest that CT scan venography, MR venography, or MR direct thrombus imaging could be used as an alternative to venography.

We recommend that patients with a negative proximal CUS (see Fig 4) undergo testing with a moderate or high sensitivity D-dimer, whole-leg US, or repeat proximal CUS in 1 week over no further testing (Grade 1B) or venography (Grade 2B). In patients with a negative proximal CUS, we suggest D-dimer rather than routine serial CUS (Grade 2B) or whole-leg US (Grade 2C). We recommend that patients with a single negative proximal CUS and positive D-dimer undergo further testing with repeat proximal CUS in 1 week or whole-leg US rather than no further testing (Grade 1B for both comparisons).

We recommend that in patients with (i) negative serial proximal CUS, (ii) a negative D-dimer following a negative initial proximal CUS, or

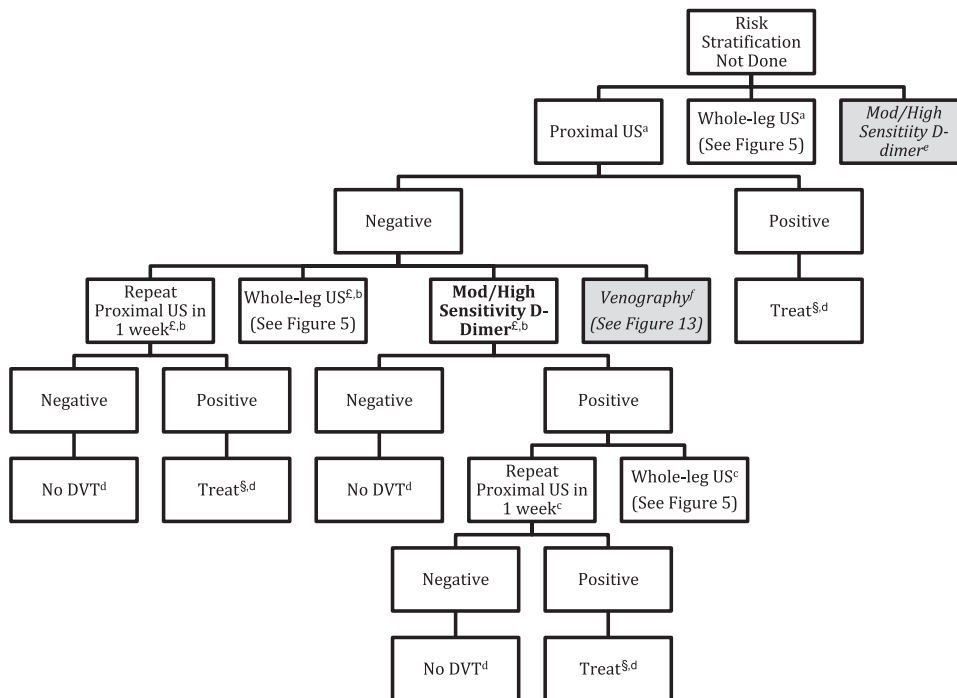


FIGURE 4. [Section 3.5] Recommendations for evaluation of suspected first lower extremity DVT: risk stratification not performed. Where there are preferred strategies, these are indicated by boldface print; less preferred strategies are indicated by italicizing/shading. §See Kearon et al.¹¹ £Use of D-dimer is suggested over use of repeat proximal US (Grade 2B) or whole-leg US (Grade 2C). ^aGrade 1B vs no testing and vs venography; Grade 2B vs D-dimer. ^bGrade 1B vs no further testing; Grade 2B vs venography. ^cGrade 1B vs no further testing. ^dGrade 1B vs venography. ^eGrade 2B for proximal US or whole-leg US over D-dimer. ^fGrade 2B for repeat proximal US, moderate or highly sensitive D-dimer, or whole-leg US over venography. ^gGrade 1B for treating DVT vs confirmatory venography. See Figure 1 legend for expansion of abbreviation.

(iii) **negative whole-leg US (see Figs 4 and 5), no further testing be performed rather than venography (Grade 1B).**

If proximal US is positive for DVT (see Fig 4), we recommend treatment rather than confirmatory venography (Grade 1B). If isolated distal DVT is detected on whole-leg US, (see Fig 5) we suggest serial testing to rule out proximal extension over treatment (Grade 2C).

Remarks: Patients with abnormal isolated distal US findings on whole-leg US who place a high value on avoiding the inconvenience of repeat testing and a low value on avoiding treatment of false-positive results are likely to choose treatment over repeat US. Patients with severe symptoms and risk factors for extension as outlined in Kearon et al¹¹ are more likely to benefit from treatment over repeat US.

3.6. In patients with suspected first lower extremity DVT, we recommend against the routine use of CT venography or MRI (Grade 1C).

4.0 DIAGNOSIS OF SUSPECTED RECURRENT LOWER EXTREMITY DVT

Recurrent leg pain is common in patients after an episode of DVT and can be caused by recurrent

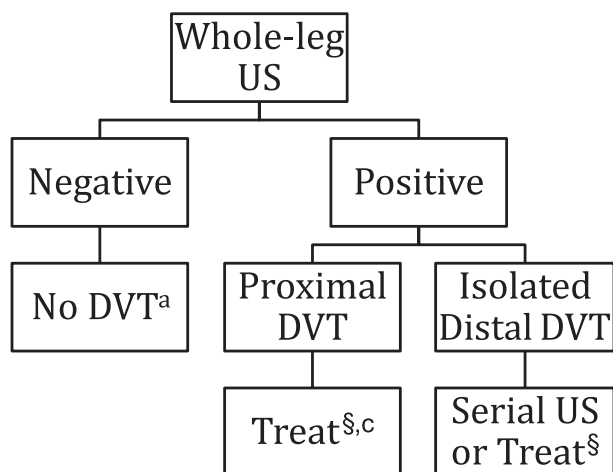


FIGURE 5. Use of whole-leg US (Referenced from Figures 1-4, 6). §See Kearon et al.¹¹ ¶If whole-leg US shows only isolated calf vein DVT, we suggest treating, rather than serial testing to rule out proximal extension only in patients with a high pretest probability or if high risk of extension or severe symptoms, see Kearon et al.¹¹ ^aGrade 1B vs repeat proximal US in 1 week, vs D-dimer testing and vs venography in patients with suspected first lower extremity DVT and a low, moderate, or unspecified pretest probability; Grade 2B vs venography and vs additional US in patients with suspected first lower extremity DVT and a high pretest probability. ^bGrade 2C vs treating DVT in patients with suspected first lower extremity DVT and a low, moderate, or unspecified pretest probability. ^cGrade 1B for treating DVT vs confirmatory venography. See Figure 1 legend for expansion of abbreviation.

disease, acute exacerbation of postthrombotic syndrome, or nonthrombotic problems. Accurate diagnosis of recurrence is important because the consequences of misdiagnosis are great. Incorrectly concluding that recurrent DVT is present commits the patient to prolonged (perhaps lifelong) anticoagulation, with its attendant costs, inconvenience, and bleeding risks. However, incorrectly concluding that recurrent DVT is absent places the patient at high risk of potentially fatal PE.

Unfortunately, few well-designed studies have been performed evaluating diagnostic strategies for suspected recurrent disease. Tables S38 and S39 summarize the methodology of diagnostic studies in patients with suspected recurrent DVT, and Table S40 provides a description of the study results. Tables S41 to S47 present the evidence profiles for the various diagnostic strategies that have been evaluated and are included in Recommendations 4.1 to 4.3. Tables 7 and 8 summarize the quality of evidence and frequency of potential clinical outcomes for the various diagnostic strategies.¹⁶⁰⁻¹⁶⁸

4.1 Venography

Although contrast venography is the reference standard in patients with an initial episode of suspected DVT,^{13,40} it can be of limited value in patients with previous disease. Although, intuitively, a normal venogram would exclude recurrent thrombosis, no empirical investigation has established this is the case. Although one might consider the presence of an intraluminal-filling defect diagnostic of acute DVT, it may be due to residual disease (scarring). Finally, as many as one-third of patients with suspected recurrence have a venogram that is considered inadequate because of nonfilling of venous segments.¹⁶⁹ In addition, as discussed in Section 2.0, venography is expensive, has complications,^{13,40,53-55,170-172} is not available in many centers, and cannot be completed in many patients for technical reasons.

4.2 Compression Ultrasonography

The evaluation of suspected ipsilateral recurrence using CUS is problematic because persistent abnormalities of the deep veins are common following a first episode of thrombosis. Prospective follow-up studies have reported residual US abnormalities (non-compressibility) in approximately 80% of patients at 3 months^{161,173} and 50% of patients 1 year after the diagnosis of proximal DVT.^{161,173-175} Thus, the presence of a noncompressible venous segment on CUS is not diagnostic of recurrent thrombosis, and recurrence can only be confirmed if there is evidence of new thrombus formation.

Table 7—[Sections 4.1-4.3] Summary of Findings for Diagnostic Studies in Patients With Suspected Recurrent Lower Extremity DVT: Accuracy Studies

Criteria	Population and Reference Standard	No. of Studies (Participants)	Quality of Evidence	Illustrative Comparative Numbers: Effect/1,000 ^a			
				True Positives (Correctly Classified as Having DVT)	True Negatives (Correctly Classified as Not Having DVT)	False Positives (Incorrectly Classified as Having DVT)	False Negatives (Incorrectly Classified as Not Having DVT)
New noncompressible segment or increased residual venous diameter of 1-2 mm ^b	Population: suspected recurrent DVT	1 Study (16 participants) ⁽⁶⁰⁾	Low ^c	Prevalence 5%, 14	Prevalence 5%, 741	Prevalence 5%, 209	Prevalence 5%, 36
	Reference standard: venography			Prevalence 17%, 49 Prevalence 53%, 154	Prevalence 17%, 647 Prevalence 53%, 367	Prevalence 17%, 183 Prevalence 53%, 103	Prevalence 17%, 121 Prevalence 53%, 376
New noncompressible segment or increased residual venous diameter of ≥ 2 mm ^d	Population: suspected recurrent DVT	2 Studies (115 participants) ^(61,62)	Low ^c	Prevalence 5%, 49	Prevalence 5%, 921	Prevalence 5%, 29	Prevalence 5%, 5
	Reference standard: venography			Prevalence 17%, 456 Prevalence 53%, 482	Prevalence 17%, 805 Prevalence 53%, 155	Prevalence 17%, 25 Prevalence 53%, 14	Prevalence 17%, 15 Prevalence 53%, 49
New noncompressible segment or increased residual venous diameter of > 4 mm ^f	Population: suspected recurrent DVT	2 Studies ^(60,63) ; however, estimates of both sensitivity and specificity only in 1 (16 participants) ⁽⁶³⁾	Moderate ^g	Prevalence 5%, 36	Prevalence 5%, 950	Prevalence 5%, 0	Prevalence 5%, 14
	Reference standard: venography			Prevalence 17%, 121 Prevalence 53%, 376	Prevalence 17%, 830 Prevalence 53%, 470	Prevalence 17%, 0 Prevalence 53%, 0	Prevalence 17%, 50 Prevalence 53%, 154

GRADE Working Group grades of evidence: High quality: Further research is very unlikely to change our confidence in the estimate of effect. Moderate quality: Further research is likely to have an important impact on our confidence in the estimate of effect and may change the estimate. Low quality: Further research is very likely to have an important impact on our confidence in the estimate of effect and is likely to change the estimate. See Table 1 and 3 legends for expansion of abbreviation.

^aPrevalences for high (53%), moderate (17%), and low (5%) taken from Wells et al.¹⁰

^bBased on a specificity of 78% (95% CI, 45%-94%) and sensitivity of 29% (95% CI, 8%-64%).

^cSerious limitations (published only in abstract form, unclear if consecutive or selected patients, technique requires local expertise and previous CUS for comparison), single study, serious indirectness (accuracy study only; no management studies), and moderate imprecision (wide 95% CI).

^dBased on a specificity of 97% and sensitivity of 91%.

^eSerious limitations (one study published only in abstract form,⁶² unclear if consecutive or selected patients; technique requires local expertise and previous CUS for comparison), serious indirectness (accuracy study only; no management studies), and moderate imprecision (wide 95% CI).

^fBased on a specificity of 100% (95% CI, 70%-100%) and sensitivity of 71% (95% CI, 36%-92%)⁽⁶⁰⁾; positive predictive value only of 100% (95% CI, 84%-100%)⁽⁷⁰⁾

^gSerious limitations (published only in abstract form, unclear if consecutive or selected patients; technique requires local expertise and previous CUS for comparison), single study, serious indirectness (accuracy study only; no management studies), and very serious imprecision (wide 95% CI).

Table 8—[Sections 4.1-4.3] Summary of Findings for Diagnostic Studies in Patients with Suspected Recurrent Lower Extremity DVT: Prospective Management Cohort Studies

Diagnostic Strategy Used to Exclude Recurrent DVT	No. of Participants (Studies)	Outcome	Incidence of VTE During Follow-up Among Patients Judged to Have Recurrent DVT Excluded (ie, Post-TP of DVT), % (95% CI)%	Quality of Evidence
Negative serial proximal CUS ¹⁶²⁻¹⁶⁵	Normal serial US			Moderate ^a
	Day of presentation, day 2 [± 1], day 7 [± 1]: 150 (1) ¹⁶³	VTE diagnosed during 6 mo of follow-up ¹⁶³	1.3 (95 CI, 0.02-4.7) ¹⁶³	
	Day of presentation, day 1-3 and 6-10 (in patients with a positive DD): 129 (2) ¹⁶⁵	VTE diagnosed during 3 mo of follow-up ¹⁶⁵	2.3 (95 CI, 0.8-6.6) ¹⁶⁵	
	Normal or unchanged/improved residual venous diameter serial US			Low ^b
	Day of presentation, day 2 [± 1], day 7 [± 1]: 86 (1) ¹⁶²	VTE diagnosed during 6 mo of follow-up ¹⁶²	3.1 (95 CI, 0.4-10.7) ¹⁶²	
	Unchanged residual venous diameter (< 4 mm) Day of presentation and day 7: 42 (1) ¹⁶⁴	VTE diagnosed during 3 mo of follow-up ¹⁶⁴	4.8 (95 CI, 1.3-15.8) ¹⁶⁴	Low ^c
Unchanged residual venous diameter (< 4 mm increase) on proximal CUS and a negative highly sensitive DD (Biopool AutoDimer) ¹⁶⁶	75 (1)	VTE diagnosed during 3 mo of follow-up	0 (95 CI, 0-4.8)	Moderate ^d
Unlikely pre-TP and negative highly sensitive DD (STA Liatest) ¹⁶⁷	16 (1)	VTE diagnosed during 3 mo of follow-up	0 (95 CI, 9-19.4)	Low ^e
Negative highly sensitive DD	STA Liatest DD: 134 (1) ¹⁶⁸	VTE diagnosed during 3 mo of follow-up	0.75 (95 CI, 0.02-4.1)	Moderate ^f
	MDA DD: 229 (1) ¹⁶⁵		1.71 (95 CI, 0.7-4.4)	

Consequences in terms of presenting with VTE during clinical follow-up when specific strategies are used to rule out suspected recurrent DVT. GRADE Working Group grades of evidence: High quality: Further research is very unlikely to change our confidence in the estimate of effect. Moderate quality: Further research is likely to have an important impact on our confidence in the estimate of effect and may change the estimate. Low quality: Further research is very likely to have an important impact on our confidence in the estimate of effect and is likely to change the estimate. See Table 1 and 3 legends for expansion of abbreviations.

^aBates et al¹⁶⁵ published only in abstract.

^bSingle study; point estimate for post-TP of DVT > 2%; very serious imprecision, wide 95% CI.

^cSingle study; unclear if consecutive or selected patients used; point estimate for post-TP of DVT > 2%; wide 95% CI.

^dSingle-center study; wide 95% CI.

^eOnly 15% of patients presenting to the ED with suspected DVT could be managed with this strategy, single study, very wide 95% CI.

^fNo data on patients with various pre-TPs; unable to determine exact overall prevalence of recurrent DVT¹⁶⁸; published in abstract only¹⁶⁵; for both studies, wide 95% CI.

Although the finding of a new noncompressibility of the common femoral or popliteal vein when compared with a previous US is considered diagnostic of recurrence, this finding occurs in only 10% to 20% of patients with recurrent thrombosis.^{161,162,176} Although complete resolution of thrombus is slow to occur, the diameter of residual disease as assessed by CUS decreases substantially (by up to 62% in the common femoral vein and by as much as 50% in the popliteal vein) during the first 3 months of therapy.¹⁶¹

Two small studies suggest that recurrent ipsilateral DVT can be diagnosed in the presence of new noncompressibility of a previously normal popliteal

or common femoral vein and/or a ≥ 2-mm increase in the residual venous diameter of one of these two veins (when measured in the transverse plane during maximal compression) and compared with the results of previous venous US (specificity of 100% and 95% against a reference standard of venography in both studies).^{161,162} However, another study does not support these findings (14% of those with a positive test proved not to have thrombosis when venography performed).¹⁶³ Further, in a study assessing interobserver agreement on measurement of residual vein diameter, the mean difference between paired measurements was 2.2 mm (95th centile, 8.0 mm).¹⁷⁷

An increase in venous diameter ≥ 4 mm during compression compared with a previous result on venous US appears more accurate for the diagnosis of recurrence (specificity of 100%).^{160,163} However, interobserver variability in the measurement of residual thrombus suggests that, in the absence of a new noncompressible common femoral or popliteal vein, even an apparent increase in residual venous diameter of 4 mm may be associated with false positives. Furthermore, for a quantitative US assessment to be performed, a previous US must be available for comparison.

Rigorous evaluation and validation of other proposed venous US criteria for the diagnosis of recurrent DVT (eg, changes in thrombus length, Doppler flow, and intraluminal appearance) have not been published. Moreover, like residual vein diameter assessment, these characteristics have only moderate interobserver agreement.^{177,178}

Extrapolating from studies in symptomatic patients with a suspected first DVT who have normal results on serial CUS, a similar strategy is expected to reliably exclude DVT in patients with suspected recurrence. Theoretically, development of collateral vessels in patients with previous disease might result in false-negative results (ie, a normal collateral vessel may be mistaken for one of the deep veins, preventing the ultrasonographer from detecting new DVT). Nonetheless, several management cohort studies suggest that it is safe to withhold anticoagulant therapy in patients with suspected recurrent DVT who have repeatedly normal results or unchanged residual venous diameter measurements on serial testing performed either on days 2 (± 1) and 7 (± 1),^{162,163} day 7,^{32,164} or days 1 to 3 and 7 to 10¹⁶⁵ (frequency of false negatives, 1%,¹⁶² 2%,¹⁶⁵ 3%,¹⁶³ and 5%¹⁶⁴).

4.3 Pretest Probability Assessment

Although the most recent version of the Wells pretest probability model for suspected DVT includes a history of previous VTE as one of items used to determine clinical probability,³² it has not been validated in a large population of patients with suspected recurrence.

4.4 D-Dimer Alone and in Combination With Pretest Probability Assessment or CUS

D-Dimer assays have been less extensively evaluated in patients with suspected recurrent DVT than in those with a suspected first event. In many patients, D-dimer levels appear to return to normal values within 3 months of starting treatment of acute DVT¹⁷⁹ and remain within the normal range after anticoagulant therapy is withdrawn in the majority of patients.¹⁸⁰

Therefore, D-dimer testing should be useful in patients with suspected recurrence.

Five prospective cohort management studies have reported results for strategies involving D-dimer testing in patients with suspected recurrent DVT.^{32,165,167-168} In two studies in which a negative sensitive D-dimer was used either in combination with an unlikely pretest probability using the modified Wells model ($n = 16$ patients)¹⁶⁷ or a CUS at presentation that was either normal or showed an increase in residual diameter of < 4 mm ($n = 75$)¹⁶⁶ to exclude recurrence, no patients experienced VTE during 3 months of follow-up. However, the first strategy may have limited usefulness, as the combination of D-dimer and pretest probability assessment was able to exclude recurrence in only 15% of patients.¹⁶⁷ Two larger prospective cohort studies suggest that negative results of sensitive assays exclude DVT in outpatients with suspected recurrent DVT (false-negative frequencies of 2%¹⁶⁵ and 5%¹⁶⁸). In a randomized trial of 1,096 outpatients with suspected DVT, of whom 102 had prior VTE, the combination of an unlikely pretest probability (using the modified Wells model) and negative D-dimer (either moderate or high sensitivity) had a frequency of VTE during 3-month follow-up of 0.9% (95% CI, 0.3%-3.3%). Results for the 102 patients with suspected recurrence were not presented separately.

4.5 CT Scan Venography

There are no accuracy or management studies of CT scan venography in patients with suspected recurrent DVT.

4.6 MRI

One prospective study of 43 patients with a first episode of DVT suggests that the high T1 signal normalizes within 6 months.¹⁸¹ However, there has been no evaluation of this technique's accuracy in patients with suspected recurrent DVT. MR venography has not been evaluated in patients with suspected DVT.

Recommendations (see Figs 6-9)

4.1. In patients suspected of having recurrent lower extremity DVT (see Fig 6), we recommend initial evaluation with proximal CUS or a highly sensitive D-dimer over venography, CT venography or MRI (all Grade 1B).

Remarks: Initial D-dimer testing with a high-sensitivity assay is preferable if prior US is not available for comparison.

If the highly sensitive D-dimer is positive (see Fig 7), we recommend proximal CUS over

venography, CT venography, or MRI (Grade 1B for all comparisons).

In patients with suspected recurrent lower extremity DVT in whom initial proximal CUS is negative (normal or residual diameter increase of <2 mm) (see Fig 6), we suggest at least one further proximal CUS (day 7 ± 1) or testing with a moderately or highly sensitive D-dimer (followed by repeat CUS [day 7 ± 1] if positive) rather than no further testing or venography (Grade 2B).

Remarks: In patients with an abnormal proximal US at presentation that does not meet the criteria for the diagnosis of recurrence, an additional proximal CUS on day 2 ± 1 in addition to that on (day 7 ± 1) may be

preferred. Patients who place a high value on an accurate diagnosis and a low value on avoiding the inconvenience and potential side effects of a venography are likely to choose venography over missed diagnosis (in the case of residual diameter increase of <2 mm).

We recommend that patients with suspected recurrent lower extremity DVT and a negative highly sensitive D-dimer or negative proximal CUS and negative moderately or highly sensitive D-dimer or negative serial proximal CUS (see Figs 6 and 7) undergo no further testing for suspected recurrent DVT rather than venography (Grade 1B).

If CUS of the proximal veins is positive (see Figs 6 and 7), we recommend treating for DVT and

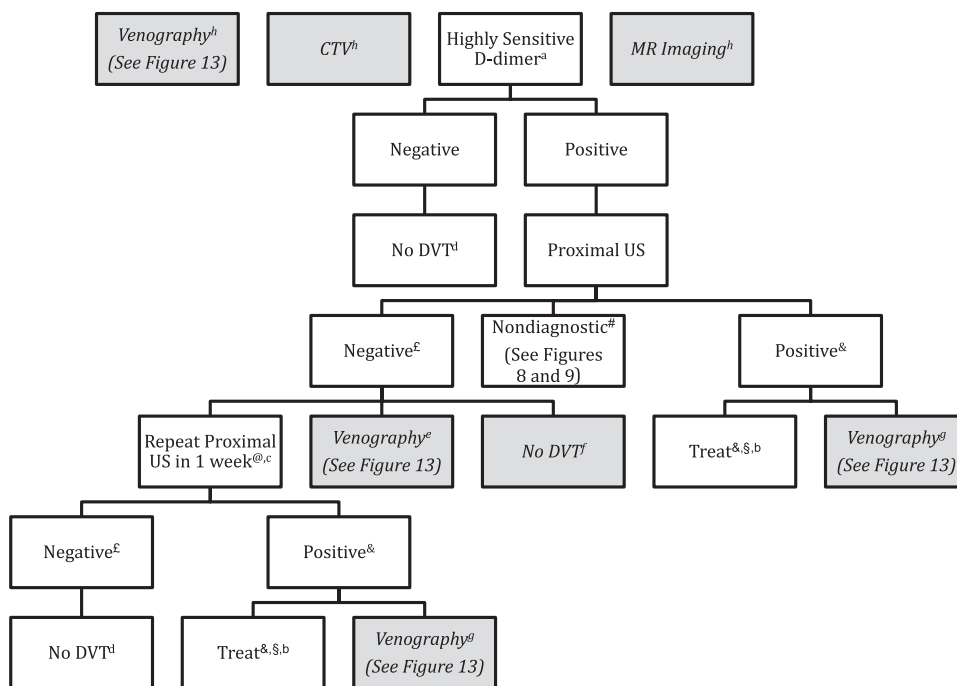


FIGURE 7. [Section 4.1] Recommendations for evaluation of suspected lower extremity recurrent DVT: highly sensitive D-dimer as initial test. Where there are preferred strategies, these are indicated by boldface print; less preferred strategies are indicated by italicizing/shading. §See Kearon et al.¹¹ £“Negative” refers to a normal US or an area of prior noncompressibility with a stable or decreased residual diameter or an interval increase in residual diameter of <2 mm. #“Nondiagnostic” refers to a technically limited US, an area of prior noncompressibility with increase in residual venous diameter of <4 mm but ≥2 mm, or an area of prior noncompressibility without prior measurement of residual diameter for comparison. &“Positive” refers to a new noncompressible segment or an area of prior noncompressibility with an interval increase in residual diameter of ≥4 mm. @Consider additional serial proximal US. ^aGrade 1B vs venography, CTV, or MR venography; preferred initial assay if prior US not available for comparison. ^bGrade 1B for treating DVT vs venography if new noncompressible segment in the common femoral or popliteal vein; Grade 2B for treating DVT vs venography for a ≥4-mm increase in venous diameter during compression compared with that in the same venous segment on a previous result. ^cGrade 2B vs no further testing and vs venography. ^dGrade 1B vs further testing with venography. ^eGrade 2B for at least one additional proximal US over venography. ^fGrade 2B for at least one additional proximal US over no further testing. ^gGrade 1B for treating DVT over venography if new noncompressible segment in the common femoral or popliteal vein; Grade 2B for treating DVT over venography for a ≥4-mm increase in venous diameter during compression compared with that in the same venous segment on a previous result. ^hGrade 1B for highly sensitive D-dimer (or proximal US; see Figure 6) over venography, CTV, or MRI. See Figure 1 and 6 legends for expansion of abbreviations.

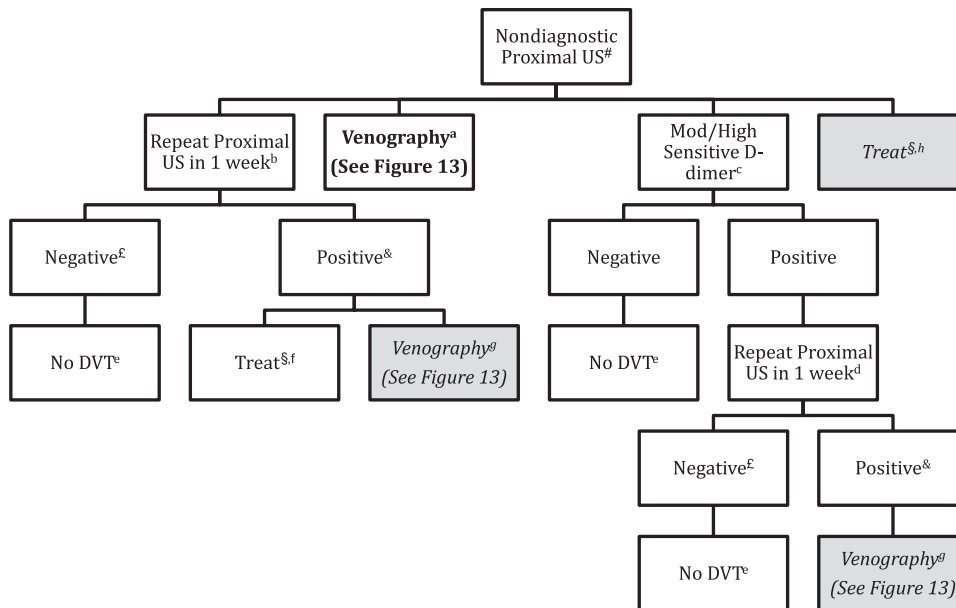


FIGURE 8. [Section 4.2] Recommendations for evaluation of suspected lower extremity recurrent DVT: evaluation following nondiagnostic proximal US and prior US result available for comparison. Where there are preferred strategies, these are indicated by boldface print; less preferred strategies are indicated by italicizing/shading. §See Kearon et al.¹¹ #Previous US with residual diameter measurements is available for comparison. Current US is nondiagnostic (technically limited or only abnormality an area of prior noncompressibility with increase in residual venous diameter of < 4 mm but ≥ 2 mm). ^c“Negative” refers to a normal US or an area of prior noncompressibility with a stable or decreased residual diameter or an interval increase in residual diameter of < 2 mm. [&]“Positive” refers to a new noncompressible segment or an area of prior noncompressibility with an interval increase in residual diameter of ≥ 4 mm. ^aGrade 1B vs treating for DVT and vs alternative test strategies. ^bGrade 2B vs treating for DVT and vs alternative test strategies. ^cGrade 2B vs treating for DVT and vs alternative test strategies. ^dGrade 2B vs no further testing and vs venography. ^eGrade 1B vs further testing with venography. ^fGrade 1B for treating DVT vs venography if new noncompressible segment in the common femoral or popliteal vein; Grade 2B for treating DVT vs venography for a ≥ 4 -mm increase in venous diameter during compression compared with that in the same venous segment on a previous result. ^gGrade 2B for treating DVT over venography if a ≥ 4 -mm increase in venous diameter during compression compared with that in the same venous segment on a previous result (Grade 1B for treating DVT over venography if new noncompressible segment in the common femoral or popliteal vein). ^hGrade 2B for repeat proximal US in 1 week or moderate or highly sensitive D-dimer over treating for DVT (Grade 1B for venography over treating for DVT). See Figure 1 legend for expansion of abbreviation.

performing no further testing over performing confirmatory venography (Grade 1B for the finding of a new noncompressible segment in the common femoral or popliteal vein, Grade 2B for a ≥ 4 -mm increase in venous diameter during compression compared with that in the same venous segment on a previous result).

Remarks: Patients with US abnormalities at presentation that do not include a new noncompressible segment who place a high value on an accurate diagnosis and a low value on avoiding the inconvenience and potential side effects of a venography are likely to choose venography over treatment (in the case of a ≥ 4 -mm increase in venous diameter).

4.2. In patients with suspected recurrent lower extremity DVT and abnormal but nondiagnostic US results (eg, an increase in residual venous

diameter of < 4 but ≥ 2 mm) (see Fig 8), we recommend further testing with venography, if available (Grade 1B); serial proximal CUS (Grade 2B) or testing with a moderately or highly sensitive D-dimer with serial proximal CUS as above if the test is positive (Grade 2B), as opposed to other testing strategies or treatment.

4.3. In patients with suspected recurrent ipsilateral DVT and an abnormal US without a prior result for comparison (see Fig 9), we recommend further testing with venography, if available (Grade 1B) or a highly sensitive D-dimer (Grade 2B) over serial proximal CUS. In patients with suspected recurrent ipsilateral DVT and an abnormal US without prior result for comparison and a negative highly sensitive D-dimer, we suggest no further testing over venography (Grade 2C). In patients with suspected recurrent ipsilateral

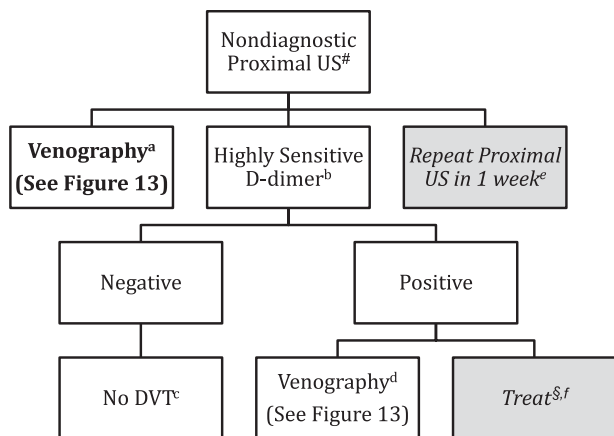


FIGURE 9. [Section 4.3] Recommendations for evaluation of suspected lower extremity recurrent DVT: evaluation following nondiagnostic proximal US and prior US result not available for comparison. Where there are preferred strategies, these are indicated by boldface print; less preferred strategies are indicated by italicizing/shading. §See Kearon et al.¹¹ Previous US with residual diameter measurements is not available for comparison. Current US is nondiagnostic (technically limited or only abnormality an area of prior noncompressibility). ^aGrade 1B vs repeat proximal US in 1 week. ^bGrade 2C vs repeat proximal US in 1 week. ^cGrade 2C vs further testing with venography. ^dGrade 2C vs treating for DVT. ^eGrade 2B for highly sensitive D-dimer (Grade 1B for venography) over repeat proximal US in 1 week. ^fGrade 2C for venography over treating for DVT. MRV = magnetic resonance venography. See Figure 1 legend for expansion of other abbreviation.

DVT and an abnormal US without prior result for comparison and a positive highly sensitive D-dimer, we suggest venography if available over empirical treatment of recurrence (Grade 2C).

Remarks: Patients who place a high value on avoiding the inconvenience and potential side effects of a venography are likely to choose treatment over venography.

5.0 DIAGNOSIS OF PREGNANCY-RELATED DVT

Roughly two-thirds of all pregnancy-related DVT occur antepartum, with risk distributed across all three trimesters.¹⁸² During pregnancy, DVT is found in the left leg in > 80% of cases.^{182,183} A recent systematic review confirmed a high frequency of iliofemoral (64%) and isolated iliac vein (17%) thromboses among those with confirmed DVT.¹⁸³

Tables S48 and S49 summarize the methodology of diagnostic studies in patients with suspected pregnancy-related DVT; Table S50 provides a description of the study results. Evidence profiles for the various diagnostic strategies that have been evaluated are included in Tables S51 to S55. Tables 9 and 10 summarize the quality of evidence and potential clinical outcomes for the various diagnostic strategies.¹⁸⁴⁻¹⁸⁷

5.1 Venography

Although venography is the reference standard test for the diagnosis and exclusion of DVT,^{13,40} concerns about fetal radiation exposure during testing have limited the number of studies involving this technique in pregnant women with suspected DVT. Potential adverse effects of in utero radiation exposure include oncogenicity and teratogenicity. Investigators using simulation techniques have calculated the radiation to the fetus during the performance of unilateral venography with abdominal shielding to be < 0.05 rads and 0.32 rads when shielding is removed.¹⁸⁸ Radiation doses of ≤ 5 rads do not appear to be associated with an increased risk of pregnancy loss,^{189,190} and it has been suggested that the risk of fetal malformation only increases above background levels at radiation doses > 15 rads.^{189,190} However, studies have reported up to a twofold increase in the risk of childhood malignancies with radiation exposures of up to 5 rads.¹⁸⁸ In absolute terms, this equates to a potential increase in the incidence of cancer in the first year of life from 0.1% to 0.2%.¹⁹¹ A recent record linkage of administrative and health-care use databases in Ontario, Canada that identified 1.8 million mother-child pairs reported no significant increase in the risk of cancer in children of mothers who underwent CT scan or radionuclide imaging in pregnancy compared with offspring of mothers with no exposure, although a small harmful effect could not be excluded (adjusted hazard ratio: 0.68; 95% CI, 0.25-1.80).¹⁹² These data suggest that a fear of fetal irradiation as consequence of maternal venography is likely overstated.

5.2 Compression Ultrasonography

Diagnostic imaging algorithms for DVT in the non-pregnant population are often extrapolated to pregnant women. However, these strategies may be inadequate as they do not take into account the increased frequency of pelvic and iliac vein thrombosis seen during pregnancy and the lack of sensitivity of standard CUS for DVT isolated to these areas.^{193,194} Although modifications of standard CUS technique that include Valsalva maneuvers and the assessment of flow changes with respiration can be used to assess for patency of the iliac veins,^{186,195-197} the accuracy of these techniques has not been rigorously assessed.

A multicentre prospective cohort study of 149 pregnant women with suspected first DVT evaluated the role of proximal CUS in the exclusion of DVT.¹⁸⁶ All patients underwent CUS with compression along the proximal veins and the calf trifurcation. Direct imaging and Doppler flow examination of the iliac veins were conducted if isolated iliac vein thrombosis was suspected. DVT was diagnosed when a venous

Table 9—[Sections 5.1-5.3] Summary of Findings of Diagnostic Studies in Patients With Suspected Pregnancy-Related DVT: Accuracy Studies

Criteria	Population and Reference Standard	No. of Studies (Patients)	Quality of Evidence	Illustrative Comparative Numbers: Effect/1,000 ^a			
				True Positives (Correctly Classified as Having DVT)	True Negatives (Correctly Classified as Not Having DVT)	False Positives (Incorrectly Classified as Having DVT)	False Negatives (Incorrectly Classified as Not Having DVT)
Clinical model ^b	Population: suspected pregnancy-related DVT	1 (195) ¹⁸⁴	Low ^c	Prevalence 1.5%, 15	Prevalence 1.5%, 493	Prevalence 1.5%, 492	Prevalence 1.5%, 0
	Reference standard: proximal CUS and 3 mo of follow-up			Prevalence 8.7%, 87	Prevalence 8.7%, 457	Prevalence 8.7%, 456	Prevalence 8.7%, 0
Highly sensitive DD (standard threshold) ^d	Population: suspected pregnancy-related DVT	1 (249) ¹⁸⁵	Low ^e	Prevalence 1.5%, 15	Prevalence 1.5%, 101	Prevalence 1.5%, 884	Prevalence 1.5%, 0
	Reference standard: proximal CUS and 3 mo of follow-up			Prevalence 8.7%, 87	Prevalence 8.7%, 84	Prevalence 8.7%, 819	Prevalence 8.7%, 0
Moderately sensitive DD	Population: suspected pregnancy-related DVT	1 (149) ¹⁸⁶	Low ^f	Prevalence 1.5%, 15	Prevalence 1.5%, 591	Prevalence 1.5%, 394	Prevalence 1.5%, 0
	Reference standard: proximal CUS and 3 mo of follow-up			Prevalence 8.7%, 87	Prevalence 8.7%, 548	Prevalence 8.7%, 306	Prevalence 8.7%, 0

GRADE Working Group grades of evidence: High quality: Further research is very unlikely to change our confidence in the estimate of effect. Moderate quality: Further research is likely to have an important impact on our confidence in the estimate of effect and may change the estimate. Low quality: Further research is very likely to have an important impact on our confidence in the estimate of effect and is likely to change the estimate. See Table 1 and 3 legends for expansion of abbreviation.

^aPrevalences taken from Chan et al.¹⁸⁴

^bBased on a specificity of 50% (95% CI, 43%-58%) for absence of left leg symptoms, difference in calf circumference of at least 2 cm, and first trimester presentation and sensitivity of 100% (95% CI, 71%-100%) for at least one of these characteristics.

^cVery serious limitations (not clearly a sample of consecutive patients, accepted reference standard not used, reference standard results not blinded, internal validation only, small number of events [17]), single study, serious indirectness (accuracy study only, no management studies), and very serious imprecision (wide 95% CI).

^dBased on a specificity of 10.3% (95% CI, 6.6%-15.5%) and sensitivity of 100% (95% CI, 74.7%-100%) for the VIDAS DD using the standard cut point of 0.5 µg FEU/mL.

^eVery serious limitations (not clearly a sample of consecutive patients, accepted reference standard not used, frozen samples, reference standard results not blinded, small number of events [15]), single study, serious indirectness (accuracy study only, no management studies), and very serious imprecision (wide 95% CI).

^fBased on a specificity of 60% (95% CI, 52%-68%) and sensitivity of 100% (95% CI, 77%-100%) for the SimpliRED DD.

^gSerious limitations (accepted reference standard not used, frozen samples, reference standard results not blinded, small number of events [13]), single study, serious indirectness (accuracy study only, no management studies), and very serious imprecision (wide 95% CI).

Table 10—[Sections 5.1-5.3] Summary of Findings of Diagnostic Studies in Patients with Suspected Pregnancy-Related DVT: Prospective Cohort Management Studies

Diagnostic Strategy Used to Exclude DVT	Number of Participants (Studies)	Outcome	Incidence of VTE During Follow-up Among Those Judged to Have DVT Excluded (ie, Post-TP of DVT), % (95% CI)	Quality of Evidence
Negative serial CUS of the proximal veins and calf trifurcation (with imaging of the iliac veins in women with symptoms of isolated iliac vein thrombosis) on day of presentation, day 3, and day 7 ¹⁸⁶	149 (1)	VTE diagnosed during 3 mo of follow-up	0.7 (95% CI, 0.1-4.0)	Moderate ^a
Single whole-leg US ¹⁸⁷	194 (1)	VTE diagnosed during 3 mo of follow-up	1.7 (95% CI, 0.6-5.0)	Low ^b

Consequences in terms of presenting with VTE during clinical follow-up when specified strategies are used to rule out pregnancy-related DVT. GRADE Working Group grades of evidence: High quality: Further research is very unlikely to change our confidence in the estimate of effect. Moderate quality: Further research is likely to have an important impact on our confidence in the estimate of effect and may change the estimate. Low quality: Further research is very likely to have an important impact on our confidence in the estimate of effect and is likely to change the estimate. See Table 1 and 3 legends for expansion of abbreviations.

^aSerious limitations (proportion of patients who underwent single CUS vs those who underwent serial testing on days 3 and 7 not specified and proportion of patients who required imaging of the iliac veins not specified), single study with overall prevalence of DVT of 8.7%, wide 95% CI.

^bSerious limitations (an unspecified number were postpartum, of 176 women without DVT at presentation, three received full-dose anticoagulants despite negative US, complete follow-up only on 164 women), single study, study published only in abstract.

segment was noncompressible, when iliac vein thrombus was visualized, or when flow was absent in the iliac veins. Some patients with negative US at presentation underwent follow-up testing on day 3 and day 7, according the clinician's standard of practice (proportion not specified). All patients with normal CUS had anticoagulants withheld and were followed for 3 months. Twelve patients were diagnosed with DVT on CUS either at presentation or during serial testing. The false-negative rate of the CUS testing strategy during 3 months of follow-up was 0.7% (95% CI, 0%-4%).

Two studies^{187,198} have examined the role of complete whole-leg US in the exclusion of pregnancy-related DVT. Both, however, have important limitations (Table S52).

5.3 Pretest Probability

Studies evaluating clinical prediction rules have excluded pregnant women. These models might not be applicable in this patient population because pregnant women frequently develop leg swelling unrelated to thrombosis and are less likely to have comorbidities included as risk factors in these models.¹⁹⁹

In a multicenter accuracy study of 194 unselected pregnant women with suspected first DVT, of whom 17 had objectively confirmed disease, experienced physicians were able to empirically classify patients into low- and non-low-risk categories.¹⁸⁴ The majority of patients were classified as having a low pretest probability (67.5%). In this group, the prevalence of

DVT was 1.5% (95% CI, 0.4%-5.4%) and the likelihood ratio associated with a low pretest probability was 0.16 (95% CI, 0.04-0.59). DVT was diagnosed in 24.6% of those with a moderate or high pretest probability. The likelihood ratio of a positive test (moderate or high pretest probability) was 12.9 (95% CI, 5.9-28.2). Inexperienced physicians are likely to be less accurate in their assessments.

The investigators identified three variables for inclusion in their model: (1) left leg symptoms (adjusted OR [aOR], 44.3; 95% CI, 3.2-609.7), (2) a difference in calf circumference ≥ 2 cm (aOR, 26.9; 95% CI, 6.1-118.5), and (3) first trimester presentation (aOR, 63.4; 95% CI, 7.1-401.0). Among the 17 pregnant women with confirmed DVT, all had at least one of these variables. With none of these criteria, DVT was never diagnosed (0%; 95% CI, 0%-4.2%). With one variable, DVT occurred in 16.4% of cases (95% CI, 10.5%-24.7%), whereas the frequency of thrombosis was 58.3% (95% CI, 35.8%-75.5%) when two or three criteria were present. Although the authors conducted an internal bootstrap validation, this model has not undergone prospective validation in an independent population.

5.4 D-Dimer

Although D-dimer has assumed an increasingly prominent role in the exclusion of acute DVT in the nonpregnant population, it has not yet been rigorously evaluated in pregnant patients. D-Dimer levels increase with gestational age and during complicated

pregnancies.²⁰⁰⁻²⁰³ This reduces the test's specificity, and by the third trimester, only a minority of healthy pregnant women will have a negative D-dimer result when highly sensitive assays and the same cut point as in the nonpregnant population are used.²⁰³⁻²⁰⁶

A prospective cohort study of a moderately sensitive but more specific D-dimer assay for DVT during pregnancy reported a sensitivity of 100% (95% CI, 77%-100%) and a specificity of 60% (95% CI, 62%-68%).¹⁸⁶ False-positive results were documented in only 51% of third-trimester patients, suggesting that this test warrants further investigation. The usefulness of this assay in pregnant women has not been evaluated in prospective management studies.

The specificity of highly sensitive D-dimer assays for pregnancy-related DVT may be improved without sacrificing sensitivity by using higher D-dimer cut-point values.¹⁸⁵ Validation in prospective management studies is required.

5.5 CT Scan Venography

CT scan venography may be useful in detecting pelvic vein thrombi in nonpregnant subjects¹²⁵ but is

associated with significant radiation exposure to the fetus.²⁰⁷ There are no accuracy or management studies of CT scan venography in this patient population.

5.6 MRI

MR direct imaging does not require gadolinium contrast and appears to have similar accuracy to venography for iliac vein thrombi in the nonpregnant population.¹⁵⁰ However, access to this technique is limited and it has not been evaluated in pregnant women with suspected DVT. Although one study has assessed agreement between MR venography (time-of-flight technique) and US,²⁰⁸ MRI has not been systematically evaluated in pregnant patients with suspected DVT.

Recommendations (see Figs 10 and 11)

5.1. In pregnant patients suspected of having lower extremity DVT (see Fig 10), we recommend initial evaluation with proximal CUS over other initial tests, including a whole-leg US (Grade 2C), moderately sensitive D-dimer (Grade

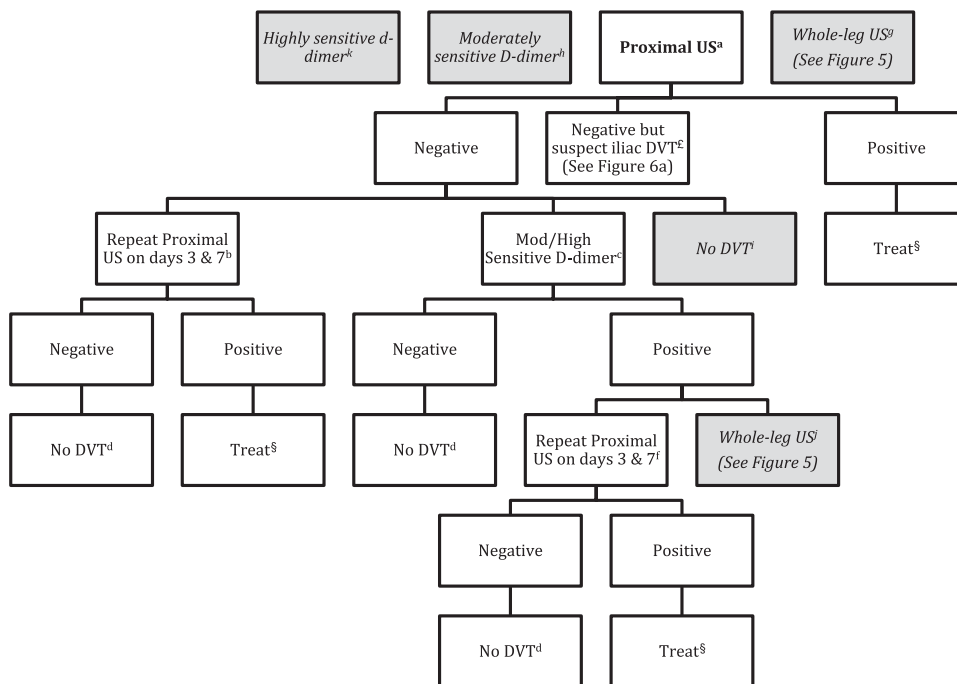


FIGURE 10. [Sections 5.1, 5.2] Recommendations for evaluation of suspected pregnancy-related lower extremity DVT. Where there are preferred strategies, these are indicated by boldface print; less preferred strategies are indicated by italicizing/shading. Venography is not generally indicated in the figure, as it is not routinely used. §See Kearon et al.¹¹ £Symptoms suggestive of iliac DVT include swelling of the entire leg, with or without flank, buttock, or back pain. ^aGrade 2C vs whole-leg US and vs moderately sensitive D-dimer; Grade 1B vs highly sensitive D-dimer and vs venography. ^bGrade 1B over no further testing. ^cGrade 2B over no further testing. ^dGrade 1B vs further testing. ^eGrade 1B vs venography; Grade 2C vs whole-leg US. ^fGrade 1B vs venography; Grade 2C vs whole-leg US. ^gGrade 2C for proximal US over whole-leg US. ^hGrade 2C for proximal US over moderately sensitive D-dimer. ⁱGrade 2B for moderate or highly sensitive D-dimer over no further testing (Grade 1B for serial proximal US over no further testing). ^jGrade 2C for serial proximal US over whole-leg US. ^kGrade 1B for serial proximal US over highly sensitive D-dimer. See Figure 1 legend for expansion of abbreviation.

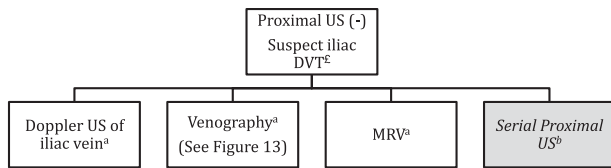


FIGURE 11. [Section 5.3] Recommendations for evaluation of suspected pregnancy-related lower extremity DVT: suspected isolated iliac vein DVT. £Symptoms suggestive of iliac DVT include swelling of the entire leg, with or without flank, buttock, or back pain. ¶Grade 2C vs standard serial proximal US. ^bGrade 2C for Doppler US of iliac vein, venography, or MRV over standard serial proximal US. See Figure 1 legend for expansion of abbreviation.

2C), **highly sensitive D-dimer** (Grade 1B), or **venography** (Grade 1B).

5.2. In pregnant patients with suspected DVT in whom initial proximal CUS is negative (see Fig 10), we suggest further testing with either serial proximal CUS (day 3 and day 7) (Grade 1B) or a sensitive D-dimer done at the time of presentation (Grade 2B) over no further testing for DVT. We recommend that patients with an initial negative proximal CUS and a subsequent negative sensitive D-dimer or negative serial proximal CUS undergo no further testing for DVT (Grade 1B) and that patients with positive D-dimer have an additional follow-up proximal CUS (day 3 and day 7), rather than venography (Grade 1B) or whole-leg US (Grade 2C).

5.3. In pregnant patients with symptoms suggestive of isolated iliac vein thrombosis (swelling of the entire leg, with or without flank, buttock, or back pain) and no evidence of DVT on standard proximal CUS (see Fig 11), we suggest further testing with either Doppler US of the iliac vein (Grade 2C), venography (Grade 2C), or direct MRI (Grade 2C), rather than standard serial CUS of the proximal deep veins.

6.0 DIAGNOSIS OF UPPER EXTREMITY DVT

Venous thrombosis involving the upper extremities is uncommon.²⁰⁹⁻²¹² The annual incidence of upper extremity DVT in the general population is estimated to be three per 100,000 persons.^{210,212-215} Secondary events, which are more common than primary thrombosis, are predominantly due to central venous catheters, pacemaker wires, and malignancies. Primary events include both idiopathic and effort-related (Paget-Schroetter syndrome) thrombosis.²¹⁶ The latter is a consequence of narrowing of the thoracic outlet at the level of the first rib and the clavicle resulting in compression of the subclavian vein.

A paucity of studies have evaluated diagnostic strategies for suspected upper extremity DVT. It is not clear that diagnostic research for lower extremity DVT can be extrapolated to upper extremity DVT. The anatomy of the upper extremity venous system creates diagnostic difficulties. The midportion of the subclavian vein runs beneath the clavicle, whereas the innominate veins and superior vena cava lie in the thoracic cavity. US visualization of these areas is difficult, and the standard diagnostic criterion of compression is impossible in these locations. Contrast venography has the ability to visualize the entire deep venous system of the upper extremity. However, as outlined in section 2.0, this technique has significant drawbacks. It would be preferable to use alternate techniques in routine clinical practice and, indeed, US is the most commonly used test.

Tables S56 and S57 summarize the methodology of diagnostic studies in patients with suspected upper extremity DVT. Table S58 provides a description of the study results, and Tables S59 to S65 present evidence profiles for the various diagnostic strategies that have been evaluated. Table 11 summarizes the quality of evidence and frequency of potential clinical outcomes for the various diagnostic strategies.²¹⁷⁻²²⁸

6.1 Ultrasonography

Upper extremity DVT is diagnosed in the presence of noncompressibility of a venous segment (CUS) or in the absence of a color or Doppler signal within the lumen of the vein (visible intraluminal thrombus) and excluded in the absence of these findings.^{216,219,223-227} Only two studies (total of 65 patients) have evaluated the accuracy of a single CUS compared with venography.^{216,219} Although the pooled sensitivity and specificity were 97% (95% CI, 90%-100%) and 94% (95% CI, 80%-99%), respectively, the studies were of low quality and the CIs are wide. No management studies have been undertaken evaluating the safety of single or serial CUS for the exclusion of upper extremity DVT.

The sensitivities and specificities of Doppler and color Doppler combined with CUS or color Doppler alone were similar to that for CUS.²²²⁻²²⁸ All of the available accuracy studies have significant limitations. No management studies using these techniques have been performed. Again, the available evidence is generally of low quality.

6.2 Clinical Pretest Probability Assessment

Evidence for the use of clinical pretest probability assessment in this patient population is of low quality. One prospective study of 214 patients evaluated a clinical score that categorized patients as “unlikely” and “likely” to have upper extremity DVT based on the presence of a central venous catheter or pacemaker,

Table 11—Summary of Findings for Diagnostic Studies in Patients with Suspected Upper Extremity DVT: Accuracy Studies

Diagnostic Test	Population and Reference Standard	No. of Studies (Participants)	Quality of Evidence	Illustrative Comparative Numbers: Effect/1,000 ^a			
				True Positives (Correctly Classified as Having DVT)	True Negatives (Correctly Classified as Not Having DVT)	False Positives (Incorrectly Classified as Having DVT)	False Negatives (Incorrectly Classified as Not Having DVT)
Clinical model ^b	Population: suspected upper extremity DVT	1 (214) ²¹⁷	Low ^c	Prevalence 5%, 39	Prevalence 5%, 608	Prevalence 5%, 342	Prevalence 5%, 11
	Reference standard: single US			Prevalence 17%, 133	Prevalence 17%, 531	Prevalence 17%, 299	Prevalence 17%, 37
Negative highly sensitive DD (VIDAS) ^d	Population: suspected upper extremity DVT	1 (52) ²¹⁸	Low ^c	Prevalence 53%, 413	Prevalence 53%, 301	Prevalence 53%, 169	Prevalence 53%, 117
	Reference standard: single US			Prevalence 5%, 50	Prevalence 5%, 133	Prevalence 5%, 817	Prevalence 5%, 0
Negative single CUS ^f	Population: suspected upper extremity DVT	2 (65) ^{216,219}	Low ^g	Prevalence 17%, 170	Prevalence 17%, 116	Prevalence 17%, 714	Prevalence 17%, 0
	Reference standard: venography			Prevalence 53%, 530	Prevalence 53%, 66	Prevalence 53%, 404	Prevalence 53%, 0
Negative single Doppler US ^h	Population: suspected upper extremity DVT	3 (101) ²²⁰	Low ⁱ	Prevalence 5%, 49	Prevalence 5%, 893	Prevalence 5%, 57	Prevalence 5%, 1
	Reference standard: venography			Prevalence 17%, 165	Prevalence 17%, 780	Prevalence 17%, 50	Prevalence 17%, 5
Negative single Doppler plus CUS ⁱ	Population: suspected upper extremity DVT	6 (320) ²²⁰	Low ^k	Prevalence 53%, 514	Prevalence 53%, 442	Prevalence 53%, 28	Prevalence 53%, 16
	Reference standard: venography			Prevalence 5%, 42	Prevalence 5%, 912	Prevalence 5%, 38	Prevalence 5%, 8
Negative MRI (time of flight) ^l	Population: suspected upper extremity DVT	1 (31) ²²¹	Low ^m	Prevalence 17%, 143	Prevalence 17%, 797	Prevalence 17%, 33	Prevalence 17%, 27
	Reference standard: venography			Prevalence 53%, 445	Prevalence 53%, 451	Prevalence 53%, 19	Prevalence 53%, 85
Negative MRI (time of flight) ^l	Population: suspected upper extremity DVT	1 (31) ²²¹	Low ^m	Prevalence 5%, 45	Prevalence 5%, 883	Prevalence 5%, 67	Prevalence 5%, 5
	Reference standard: venography			Prevalence 17%, 155	Prevalence 17%, 772	Prevalence 17%, 58	Prevalence 17%, 15
Negative MRI (time of flight) ^l	Population: suspected upper extremity DVT	1 (31) ²²¹	Low ^m	Prevalence 53%, 482	Prevalence 53%, 447	Prevalence 53%, 33	Prevalence 53%, 48
	Reference standard: venography			Prevalence 5%, 35	Prevalence 5%, 845	Prevalence 5%, 105	Prevalence 5%, 15
Negative MRI (time of flight) ^l	Population: suspected upper extremity DVT	1 (31) ²²¹	Low ^m	Prevalence 17%, 121	Prevalence 17%, 739	Prevalence 17%, 91	Prevalence 17%, 49
	Reference standard: venography			Prevalence 53%, 376	Prevalence 53%, 418	Prevalence 53%, 62	Prevalence 53%, 154

(Continued)

Table 11—Continued

Diagnostic Test	Population and Reference Standard	No. of Studies (Participants)	Quality of Evidence	Illustrative Comparative Numbers: Effect/1,000 ^a			
				True Positives (Correctly Classified as Having DVT)	True Negatives (Correctly Classified as Not Having DVT)	False Positives (Incorrectly Classified as Having DVT)	False Negatives (Incorrectly Classified as Not Having DVT)
Negative MRI (gadolinium) ^b	Population: suspected upper extremity DVT	1 (31) ^{2a1}	Low ^c	Prevalence 5%, 25	Prevalence 5%, 760	Prevalence 5%, 190	Prevalence 5%, 25
	Reference standard: venography			Prevalence 17%, 81 Prevalence 53%, 265	Prevalence 17%, 664 Prevalence 53%, 376	Prevalence 17%, 166 Prevalence 53%, 94	Prevalence 17%, 85 Prevalence 53%, 265

GRADE Working Group grades of evidence: High quality: Further research is very unlikely to change our confidence in the estimate of effect. Moderate quality: Further research is likely to have an important impact on our confidence in the estimate of effect and may change the estimate. Low quality: Further research is very likely to have an important impact on our confidence in the estimate of effect and is likely to change the estimate. See Table 1 and 3 legends for expansion of abbreviations.

^aPrevalences for high (53%), moderate (17%), and low (5%) taken from Wells et al.¹⁰

^bBased on a specificity of 64% (95% CI, 57%-72%) and sensitivity of 78% (95% CI, 68%-86%).

^cVery serious limitations (not clearly a representative sample, accepted reference standard not used, reference standard results no blinded, no data on withdrawals), single study, serious indirectness (accuracy study only, no management studies), and serious imprecision (wide 95% CI).

^dBased on a specificity of 14% (95% CI, 4%-29%) and sensitivity of 100% (95% CI, 78%-100%)

^eVery serious limitations (differential verification, accepted reference standard no used, no data on withdrawals), single study, serious indirectness (accuracy study only; no management studies), and very serious imprecision (wide 95% CI).

^fBased on a specificity of 94% (95% CI, 80%-99%) and a sensitivity of 97% (95% CI, 90%-100%).

^gVery serious limitations (in one study, CUS results unverified against reference standard in 26 of 33 patients, unclear if representative sample, unclear if reference standard test blinded, no data on withdrawals), serious indirectness (accuracy study only, no management studies), and serious imprecision (wide 95% CI).

^hBased on a specificity of 96% (95% CI, 86%-100%) and a sensitivity of 84% (95% CI, 72%-87%).

ⁱVery serious limitations (in one study, three of 12 Doppler US results unverified against reference standard and 4 of 18 verified against CT scan, rather than venography; in another study, CUS also performed with potential for bias), serious indirectness (accuracy study only, no management studies), and serious imprecision (wide 95% CI).

^jBased on a specificity of 93% (95% CI, 80%-100%) and a sensitivity of 91% (95% CI, 85%-97%).

^kVery serious limitations (in one study, 19 of 42 Duplex US results unverified against reference standard; in another, nine of 130 results unverified against reference standard and 22 of 121 Duplex results verified against venography with remainder against CT scan, MRI, and clinical follow-up; four of six studies unclear if representative patient spectrum; two of six studies unclear if blinding of reference standard and index test results), serious indirectness (accuracy study only, no management studies), and serious imprecision (wide 95% CI).

^lBased on a specificity of 89% (95% CI, 52%-100%) and a sensitivity of 71% (95% CI, 26%-96%).

^mVery serious limitations (23 of initial 44 patients were lost), single study, serious indirectness (accuracy study only, no management studies), and very serious imprecision (wide 95% CI).

ⁿBased on a specificity of 80% (95% CI, 44%-97%) and a sensitivity of 50% (95% CI, 12%-88%).

^oVery serious limitations (23 of initial 44 patients were lost), single study, serious indirectness (accuracy study only, no management studies), and very serious imprecision (wide 95% CI)

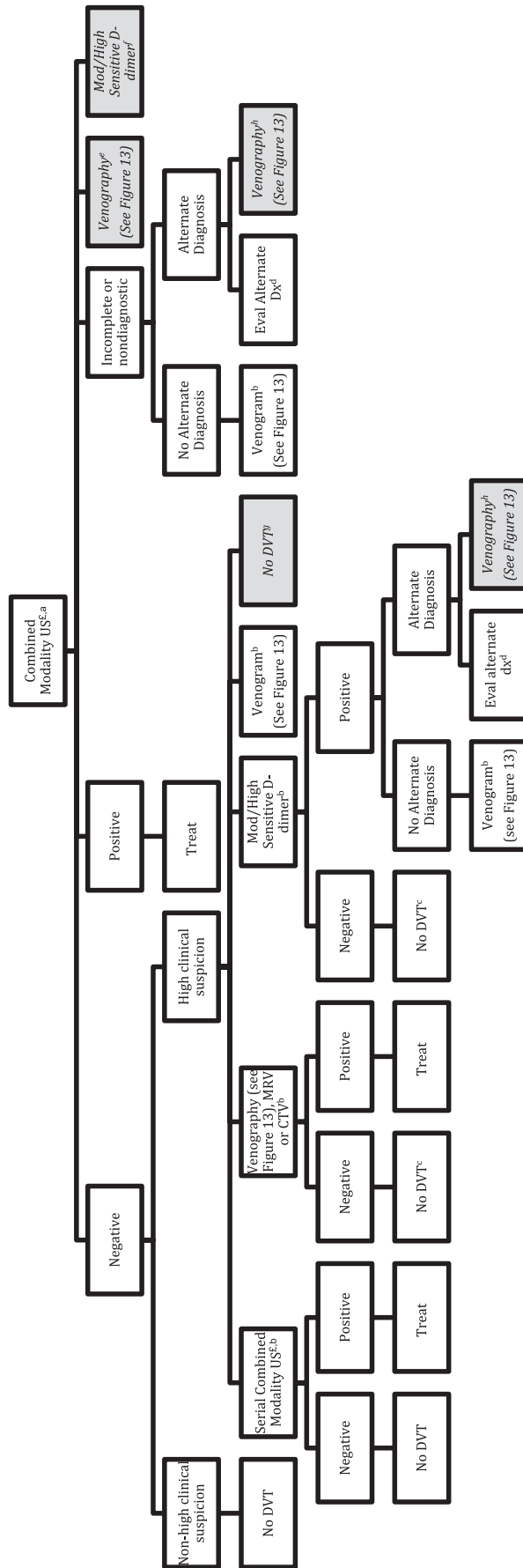


FIGURE 12. [Section 6.1, 6.2] Recommendations for evaluation of suspected upper extremity DVT. Where there are preferred strategies, these are indicated by boldface print; less preferred strategies are indicated by italicizing/shading. §See Kearon et al.¹ ¶Combined modality US refers to CUS combined with either Doppler or color Doppler. *Grade 2C vs venography, vs sensitive D-dimer and vs other strategies. ^bGrade 2C vs no further testing. ^cGrade 1C vs venography. ^dGrade 2C vs venography. ^eGrade 2C for combined modality US over venography. ^fGrade 2C for combined modality US over moderate or highly sensitive D-dimer. ^gGrade 2C for moderate or highly sensitive D-dimer, MRV, CTN, or serial combined modality US over no further testing. ^hGrade 2C for pursuing alternate diagnosis over venography. See Figure 1 legend for expansion of abbreviation.

localized pain, unilateral pitting edema, and the presence of another likely possible diagnosis.^{217,220} The sensitivity of this score was 78% (95% CI, 68%-88%), and the specificity was 64% (95% CI, 57%-72%). The score has not been evaluated in a prospective management study.

6.3 D-Dimer Testing

One study evaluated the accuracy of a rapid quantitative ELISA in 52 consecutive patients.^{218,219} Although the sensitivity was 100% (95% CI, 78%-100%), the specificity was only 14% (95% CI, 57%-72%). Moreover, Doppler combined with CUS was used as the reference standard test, making this determination potentially unreliable.

6.5 MR Venography

Time-of-flight and gadolinium-enhanced MR venography were compared with contrast venography in a 44-patient accuracy study with important limitations.^{220,221} For time of flight, the sensitivity was 71% (95% CI, 29%-96%) and the specificity was 89% (95% CI, 52%-100%). The sensitivity of gadolinium MR venography was 50% (95% CI, 12%-88%), and the specificity was 80% (95% CI, 44%-97%). No management studies have been performed with this technique.

6.6 Combinations of Tests

No studies have addressed strategies involving combinations of D-dimer, clinical assessment, and imaging studies.

Recommendations (see Fig 12)

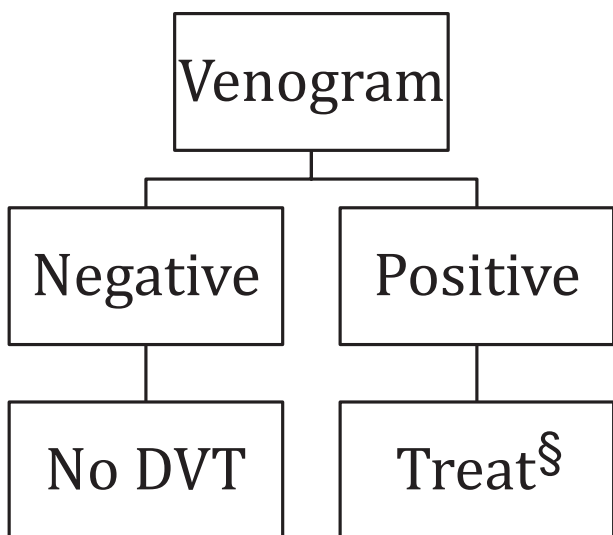


FIGURE 13. Use of venography (Referenced from Figures 1-12). §See Kearon et al.¹¹

6.1. In patients suspected of having upper extremity DVT (see Fig 12), we suggest initial evaluation with combined-modality US (compression with either Doppler or color Doppler) over other initial tests, including highly sensitive D-dimer or venography (Grade 2C).

6.2. In patients with suspected upper extremity DVT in whom initial US is negative for thrombosis despite a high clinical suspicion of DVT (see Fig 12), we suggest further testing with a moderate or highly sensitive D-dimer, serial US, or venographic-based imaging (traditional, CT scan, or MRI) rather than no further testing (Grade 2C).

In patients with suspected upper extremity DVT and an initial negative combined modality US and subsequent negative moderate or highly sensitive D-dimer or CT scan or MRI, we recommend no further testing, rather than confirmatory venography (Grade 1C). We suggest that patients with an initial negative combined-modality US and positive D-dimer or those with less than complete evaluation by US undergo venography rather than no further testing, unless there is an alternative explanation for their symptoms (Grade 2B), in which case testing to evaluate for the presence of an alternative diagnosis should be performed. We suggest that patients with a positive D-dimer or those with less than complete evaluation by US but an alternative explanation for their symptoms undergo confirmatory testing and treatment of this alternative explanation rather than venography (Grade 2C).

Remarks: Further radiologic testing (serial US or venographic-based imaging or CT scan/MRI to seek an alternative diagnosis) rather than D-dimer testing is preferable in patients with comorbid conditions typically associated with elevated D-dimer levels.

ACKNOWLEDGMENTS

Author contributions: As Topic Editor, Dr Jaeschke oversaw the development of this article, including the data analysis and subsequent development of the recommendations contained herein.

Dr Bates: contributed as Deputy Editor.

Dr Jaeschke: contributed as Topic Editor.

Dr Stevens: contributed as a panelist.

Dr Goodacre: contributed as a panelist.

Dr Wells: contributed as a panelist.

Dr Stevenson: contributed as a panelist.

Dr Kearon: contributed as a panelist.

Dr Schunemann: contributed as a panelist.

Dr Crowther: contributed as a panelist.

Dr Pauker: contributed as a panelist.

Dr Makdissi: contributed as a frontline clinician.

Dr Guyatt: contributed as a panelist.

Financial/nonfinancial disclosures: The authors of this guideline provided detailed conflict of interest information related to each individual recommendation made in this article. A grid of these disclosures is available online at http://chestjournal.chestpubs.org/content/141/2_suppl/e351S/suppl/DC1. In summary, the authors have reported to *CHEST* the following conflicts of interest: Dr Bates has received peer-reviewed research funding for studies evaluating D-dimer in the diagnosis of deep vein thrombosis, as well as research support from Trinity Biotech and Diagnostica Stago (manufacturers of D-dimer assays). Dr Goodacre was Chief Investigator for the project "Non Invasive Diagnostic Tests for DVT," funded by the UK National Institute for Health Research Health Technology Assessment Programme, reference HTA 02/03/01, from 2003-2006 (see <http://www.hta.ac.uk/1340>). Dr Stevenson participated in this project. Dr Kearon is a paid Steering Committee member for Boehringer Ingelheim VTE treatment studies, receives grant support from the National Institutes of Health for a study evaluating catheter-directed thrombolysis for treatment of DVT, and receives grant support from the Canadian Institutes of Health Research for a study evaluating D-dimer in the treatment of VTE. He has also received industry support for studies evaluating D-dimer, including grants and in-kind D-dimer kit supplies. Dr Crowther has served on various advisory boards, has assisted in the preparation of educational materials, has sat on Data Safety Monitoring Boards (DSMBs), and his institution has received research funds from the following companies: Leo Pharma, Pfizer, Boehringer Ingelheim, Bayer, Octapharma, CSL Behring, and Artisan. His personal total compensation for these activities over the last 3 years totals less than \$10,000. Further, Dr Crowther has provided expert testimony for Bayer in an area unrelated to anti-thrombotic therapy. He holds the Leo Pharma Chair in Thromboembolism Research at McMaster University. Dr Wells has received peer-reviewed and investigator-initiated industry research funding for projects related to venous thrombosis treatment. He has received honoraria for industry-sponsored (Bayer, Boehringer-Ingelheim, Pfizer, BioMerieux, sanofi-aventis) talks pertaining to venous thrombosis and has attended advisory boards for Bayer, Boehringer-Ingelheim, Pfizer, and Bristol-Myers-Squibb. Drs Guyatt and Schunemann are co-chairs of the GRADE Working Group, and Dr Jaeschke is a prominent contributor to the GRADE Working Group. Drs Stevens, Pauker, and Makkissi have reported that no potential conflicts of interest exist with any companies/organizations whose products or services may be discussed in this article.

Role of sponsors: The sponsors played no role in the development of these guidelines. Sponsoring organizations cannot recommend panelists or topics, nor are they allowed prepublication access to the manuscripts and recommendations. Guideline panel members, including the chair, and members of the Health & Science Policy Committee are blinded to the funding sources. Further details on the Conflict of Interest Policy are available online at <http://chestnet.org>.

Endorsements: This guideline is endorsed by the American Association for Clinical Chemistry, the American College of Clinical Pharmacy, the American Society of Health-System Pharmacists, the American Society of Hematology, and the International Society of Thrombosis and Hematosis.

Additional information: The supplement Tables can be found in the Online Data Supplement at http://chestjournal.chestpubs.org/content/141/2_suppl/e351S/suppl/DC1.

REFERENCES

- Anderson FA Jr, Wheeler HB, Goldberg RJ, et al. A population-based perspective of the hospital incidence and case-fatality rates of deep vein thrombosis and pulmonary embolism. The Worcester DVT Study. *Arch Intern Med.* 1991;151(5):933-938.
- Silverstein MD, Heit JA, Mohr DN, Petterson TM, O'Fallon WM, Melton LJ III. Trends in the incidence of deep vein thrombosis and pulmonary embolism: a 25-year population-based study. *Arch Intern Med.* 1998;158(6):585-593.
- McLachlin J, Richards T, Paterson JC. An evaluation of clinical signs in the diagnosis of venous thrombosis. *Arch Surg.* 1962;85:738-744.
- Nicolaidis AN, Kakkar VV, Field ES, Renney JT. The origin of deep vein thrombosis: a venographic study. *Br J Radiol.* 1971;44(525):653-663.
- Sandler DA, Martin JF, Duncan JS, et al. Diagnosis of deep-vein thrombosis: comparison of clinical evaluation, ultrasound, plethysmography, and venoscan with X-ray venogram. *Lancet.* 1984;2(8405):716-719.
- Wells PS, Hirsh J, Anderson DR, et al. Accuracy of clinical assessment of deep-vein thrombosis. *Lancet.* 1995;345(8961):1326-1330.
- Bell WR, Simon TL. Current status of pulmonary thromboembolic disease: pathophysiology, diagnosis, prevention, and treatment. *Am Heart J.* 1982;103(2):239-262.
- Alpert JS, Dalen JE. Epidemiology and natural history of venous thromboembolism. *Prog Cardiovasc Dis.* 1994;36(6):417-422.
- Carrier M, Le Gal G, Wells PS, Rodger MA. Systematic review: case-fatality rates of recurrent venous thromboembolism and major bleeding events among patients treated for venous thromboembolism. *Ann Intern Med.* 2010;152(9):578-589.
- Wells PS, Owen C, Doucette S, Fergusson D, Tran H. Does this patient have deep vein thrombosis? *JAMA.* 2006;295(2):199-207.
- Kearon C, Akl EA, Comerota AJ, et al. Antithrombotic therapy for VTE disease: antithrombotic therapy and prevention of thrombosis, 9th ed: American College of Chest Physicians evidence-based clinical practice guidelines. *Chest.* 2012;141(2)(suppl):e419S-e494S.
- Schünemann HJ, Oxman AD, Brozek J, et al; GRADE Working Group. Grading quality of evidence and strength of recommendations for diagnostic tests and strategies. *BMJ.* 2008;336(7653):1106-1110.
- Hull R, Hirsh J, Sackett DL, et al. Clinical validity of a negative venogram in patients with clinically suspected venous thrombosis. *Circulation.* 1981;64(3):622-625.
- Goodacre S, Sampson F, Stevenson M, et al. Measurement of the clinical and cost-effectiveness of non-invasive diagnostic testing strategies for deep vein thrombosis. *Health Technol Assess.* 2006;10(15):1-168.
- Goodacre S, Stevenson M, Willoo A, Sampson F, Sutton AJ, Thomas S. How should we diagnose suspected deep-vein thrombosis? *QJM.* 2006;99(6):377-388.
- Anderson DR, Kovacs MJ, Kovacs G, et al. Combined use of clinical assessment and d-dimer to improve the management of patients presenting to the emergency department with suspected deep vein thrombosis (the EDITED Study). *J Thromb Haemost.* 2003;1(4):645-651.
- Anderson DR, Wells PS, Stiell I, et al. Thrombosis in the emergency department: use of a clinical diagnosis model to safely avoid the need for urgent radiological investigation. *Arch Intern Med.* 1999;159(5):477-482.
- Bates SM, Kearon C, Crowther M, et al. A diagnostic strategy involving a quantitative latex D-dimer assay reliably excludes deep venous thrombosis. *Ann Intern Med.* 2003;138(10):787-794.
- Bernardi E, Camporese G, Büller HR, et al; Erasmus Study Group. Serial 2-point ultrasonography plus D-dimer vs whole-leg color-coded Doppler ultrasonography for diagnosing suspected symptomatic deep vein thrombosis: a randomized controlled trial. *JAMA.* 2008;300(14):1653-1659.
- Elias A, Mallard L, Elias M, et al. A single complete ultrasound investigation of the venous network for the diagnostic

- management of patients with a clinically suspected first episode of deep venous thrombosis of the lower limbs. *Thromb Haemost.* 2003;89(2):221-227.
21. Gibson NS, Schellong SM, Kheir DY, et al. Safety and sensitivity of two ultrasound strategies in patients with clinically suspected deep venous thrombosis: a prospective management study. *J Thromb Haemost.* 2009;7(12):2035-2041.
 22. Kraaijenhagen RA, Piovela F, Bernardi E, et al. Simplification of the diagnostic management of suspected deep vein thrombosis. *Arch Intern Med.* 2002;162(8):907-911.
 23. Perrier A, Desmarais S, Miron MJ, et al. Non-invasive diagnosis of venous thromboembolism in outpatients. *Lancet.* 1999;353(9148):190-195.
 24. Schellong SM, Schwarz T, Halbritter K, et al. Complete compression ultrasonography of the leg veins as a single test for the diagnosis of deep vein thrombosis. *Thromb Haemost.* 2003;89(2):228-234.
 25. Schutgens REG, Ackermans P, Haas FJLM, et al. Combination of a normal D-dimer concentration and a non-high pretest clinical probability score is a safe strategy to exclude deep venous thrombosis. *Circulation.* 2003;107(4):593-597.
 26. Sevestre MA, Labarère J, Cazez P, et al. Outcomes for inpatients with normal findings on whole-leg ultrasonography: a prospective study. *Am J Med.* 2010;123(2):158-165.
 27. Sevestre MA, Labarère J, Cazez P, et al. Accuracy of complete compression ultrasound in ruling out suspected deep venous thrombosis in the ambulatory setting. A prospective cohort study. *Thromb Haemost.* 2009;102(1):166-172.
 28. Stevens SM, Elliott CG, Chan KJ, Egger MJ, Ahmed KM. Withholding anticoagulation after a negative result on duplex ultrasonography for suspected symptomatic deep venous thrombosis. *Ann Intern Med.* 2004;140(12):985-991.
 29. Subramaniam RM, Heath R, Chou T, Cox K, Davis G, Swarbrick M. Deep venous thrombosis: withholding anticoagulation therapy after negative complete lower limb US findings. *Radiology.* 2005;237(1):348-352.
 30. Tick LW, Ton E, van Voorthuizen T, et al. Practical diagnostic management of patients with clinically suspected deep vein thrombosis by clinical probability test, compression ultrasonography, and D-dimer test. *Am J Med.* 2002;113(8):630-635.
 31. Wells PS, Anderson DR, Bormanis J, et al. Value of assessment of pretest probability of deep-vein thrombosis in clinical management. *Lancet.* 1997;350(9094):1795-1798.
 32. Wells PS, Anderson DR, Rodger M, et al. Evaluation of D-dimer in the diagnosis of suspected deep-vein thrombosis. *N Engl J Med.* 2003;349(13):1227-1235.
 33. Wells PS, Anderson DR, Bormanis J, et al. Application of a diagnostic clinical model for the management of hospitalized patients with suspected deep-vein thrombosis. *Thromb Haemost.* 1999;81(4):493-497.
 34. Walsh K, Kelaher N, Long K, Cervi P. An algorithm for the investigation and management of patients with suspected deep venous thrombosis at a district general hospital. *Postgrad Med J.* 2002;78(926):742-745.
 35. Janes S, Ashford N. Use of a simplified clinical scoring system and D-dimer testing can reduce the requirement for radiology in the exclusion of deep vein thrombosis by over 20%. *Br J Haematol.* 2001;112(4):1079-1082.
 36. MacLean S, Mulla S, Akl EA, et al. Patient values and preferences in decision making for antithrombotic therapy: a systematic review: antithrombotic therapy and prevention of thrombosis, 9th ed: American College of Chest Physicians evidence-based clinical practice guidelines. *Chest.* 2012; 141(2)(suppl):e1S-e23S.
 37. Bauer G. A venographic study of thromboembolic problems. *Acta Chir Scand.* 1940;84(suppl 61):1-75.
 38. Haeger K, Nylander G. Acute phlebography. *Triangle.* 1967; 8(1):18-26.
 39. Haeger K. Problems of acute deep venous thrombosis. I. The interpretation of signs and symptoms. *Angiology.* 1969; 20(4):219-223.
 40. Rabinov K, Paulin S. Roentgen diagnosis of venous thrombosis in the leg. *Arch Surg.* 1972;104(2):134-144.
 41. Heijboer H, Büller HR, Lensing AW, Turpie AG, Colly LP, ten Cate JW. A comparison of real-time compression ultrasonography with impedance plethysmography for the diagnosis of deep-vein thrombosis in symptomatic outpatients. *N Engl J Med.* 1993;329(19):1365-1369.
 42. Hull RD, Hirsh J, Carter CJ, et al. Diagnostic efficacy of impedance plethysmography for clinically suspected deep-vein thrombosis. A randomized trial. *Ann Intern Med.* 1985;102(1):21-28.
 43. Lensing AW, Büller HR, Prandoni P, et al. Contrast venography, the gold standard for the diagnosis of deep-vein thrombosis: improvement in observer agreement. *Thromb Haemost.* 1992;67(1):8-12.
 44. Hull R, van Aken WG, Hirsh J, et al. Impedance plethysmography using the occlusive cuff technique in the diagnosis of venous thrombosis. *Circulation.* 1976;53(4):696-700.
 45. Huisman MV, Büller HR, ten Cate JW, Heijermans HS, van der Laan J, van Maanen DJ. Management of clinically suspected acute venous thrombosis in outpatients with serial impedance plethysmography in a community hospital setting. *Arch Intern Med.* 1989;149(3):511-513.
 46. Huisman MV, Büller HR, ten Cate JW, Vreeken J. Serial impedance plethysmography for suspected deep venous thrombosis in outpatients. The Amsterdam General Practitioner Study. *N Engl J Med.* 1986;314(13):823-828.
 47. McLachlan MS, Thomson JG, Taylor DW, Kelly ME, Sackett DL. Observer variation in the interpretation of lower limb venograms. *AJR Am J Roentgenol.* 1979;132(2):227-229.
 48. Kalodiki E, Nicolaidis AN, Al-Kutoubi A, Cunningham DA, Mandalia S. How "gold" is the standard? Interobservers' variation on venograms. *Int Angiol.* 1998;17(2):83-88.
 49. Couson F, Bounameaux C, Didier D, et al. Influence of variability of interpretation of contrast venography for screening of postoperative deep venous thrombosis on the results of a thromboprophylactic study. *Thromb Haemost.* 1993;70(4):573-575.
 50. Illescas FF, Lerclerc J, Rosenthal L, et al. Interobserver variability in the interpretation of contrast venography, technetium-99m red blood cell venography and impedance plethysmography for deep vein thrombosis. *Can Assoc Radiol J.* 1990;41(5):264-269.
 51. Kilpatrick TK, Lichtenstein M, Andrews J, Gibson RN, Neerhut P, Hopper J. A comparative study of radionuclide venography and contrast venography in the diagnosis of deep vein thrombosis. *Aust N Z J Med.* 1983;23(6):641-645.
 52. Wille-Jørgensen P, Borris L, Jørgensen LN, et al. Phlebography as the gold standard in thromboprophylactic studies? A multicenter interobserver variation study. *Acta Radiol.* 1992;33(1):24-28.
 53. Lensing AW, Prandoni P, Büller HR, Casara D, Cogo A, ten Cate JW. Lower extremity venography with iohexol: results and complications. *Radiology.* 1990;177(2):503-505.
 54. AbuRahma AF, Powell M, Robinson PA. Prospective study of safety of lower extremity phlebography with nonionic contrast medium. *Am J Surg.* 1996;171(2):255-260.
 55. Berge T, Bergqvist D, Efsing HO, Hallböök T, Lindblad B, Lindhagen A. Complications of phlebography: a randomised comparison between an ionic and a non-ionic contrast medium. *Clin Radiol.* 1981;32(5):595-598.

56. Goodacre S, Sutton AJ, Sampson FC. Meta-analysis: The value of clinical assessment in the diagnosis of deep venous thrombosis. *Ann Intern Med.* 2005;143(2):129-139.
57. Kahn SR, Joseph L, Abenhaim L, Leclerc JR. Clinical prediction of deep vein thrombosis in patients with leg symptoms. *Thromb Haemost.* 1999;81(3):353-357.
58. Constans J, Nelzy ML, Salmi LR, et al. Clinical prediction of lower limb deep vein thrombosis in symptomatic hospitalized patients. *Thromb Haemost.* 2001;86(4):985-990.
59. Constans J, Boutinet C, Salmi LR, et al. Comparison of four clinical prediction scores for the diagnosis of lower limb deep venous thrombosis in outpatients. *Am J Med.* 2003;115(6):436-440.
60. Büller HR, Ten Cate-Hoek AJ, Hoes AW, et al; AMUSE (Amsterdam Maastricht Utrecht Study on thromboEmbolism) Investigators. Safely ruling out deep venous thrombosis in primary care. *Ann Intern Med.* 2009;150(4):229-235.
61. Penalzoa A, Laureys M, Wautrecht JC, Lheureux P, Motte S. Accuracy and safety of pretest probability assessment of deep vein thrombosis by physicians in training using the explicit Wells clinical model. *J Thromb Haemost.* 2006;4(1):278-281.
62. Oudega R, Hoes AW, Moons KG. The Wells rule does not adequately rule out deep venous thrombosis in primary care patients. *Ann Intern Med.* 2005;143(2):100-107.
63. Di Nisio M, Squizzato A, Rutjes AWS, Büller HR, Zwiderman AH, Bossuyt PM. Diagnostic accuracy of D-dimer test for exclusion of venous thromboembolism: a systematic review. *J Thromb Haemost.* 2007;5(2):296-304.
64. Kearon C, Julian JA, Newman TE, Ginsberg JS. Noninvasive diagnosis of deep venous thrombosis. McMaster Diagnostic Imaging Practice Guidelines Initiative. *Ann Intern Med.* 1998;128(8):663-677.
65. Cogo A, Lensing AW, Koopman MM, et al. Compression ultrasonography for diagnostic management of patients with clinically suspected deep vein thrombosis: prospective cohort study. *BMJ.* 1998;316(7124):17-20.
66. Birdwell BC, Raskob GE, Whitsett TL, et al. The clinical validity of normal compression ultrasonography in outpatients suspected of having deep venous thrombosis. *Ann Intern Med.* 1998;128(1):1-7.
67. Kakkar VV, Howe CT, Flanc C, Clarke MB. Natural history of postoperative deep-vein thrombosis. *Lancet.* 1969;2(7614):230-232.
68. Philbrick JT, Becker DM. Calf deep venous thrombosis. A wolf in sheep's clothing? *Arch Intern Med.* 1988;148(10):2131-2138.
69. Goodacre S, Sampson F, Thomas S, van Beek E, Sutton A. Systematic review and meta-analysis of the diagnostic accuracy of ultrasonography for deep vein thrombosis. *BMC Med Imaging.* 2005;5:6.
70. Geersing GJ, Janssen KJ, Oudega R, et al. Excluding venous thromboembolism using point of care D-dimer tests in outpatients: a diagnostic meta-analysis. *BMJ.* 2009;339:b2990.
71. Goodacre S, Sampson FC, Sutton AJ, Mason S, Morris F. Variation in the diagnostic performance of D-dimer for suspected deep vein thrombosis. *QJM.* 2005;98(7):513-527.
72. Stein PD, Hull RD, Patel KC, et al. D-dimer for the exclusion of acute venous thrombosis and pulmonary embolism: a systematic review. *Ann Intern Med.* 2004;140(8):589-602.
73. Subramaniam RM, Snyder B, Heath R, Tawse F, Sleight J. Diagnosis of lower limb deep venous thrombosis in emergency department patients: performance of Hamilton and modified Wells scores. *Ann Emerg Med.* 2006;48(6):678-685.
74. Fancher TL, White RH, Kravitz RL. Combined use of rapid D-dimer testing and estimation of clinical probability in the diagnosis of deep vein thrombosis: systematic review. *BMJ.* 2004;329(7470):821.
75. Righini M, Perrier A, De Moerloose P, Bounameaux H. D-Dimer for venous thromboembolism diagnosis: 20 years later. *J Thromb Haemost.* 2008;6(7):1059-1071.
76. Bernardi E, Prandoni P, Lensing AW, et al; The Multicentre Italian D-dimer Ultrasound Study Investigators Group. D-dimer testing as an adjunct to ultrasonography in patients with clinically suspected deep vein thrombosis: prospective cohort study. *BMJ.* 1998;317(7165):1037-1040.
77. Aguilar C, Martinez A, Martinez A, Del Rio C, Vazquez M, Rodriguez FJ. Diagnostic value of d-dimer in patients with a moderate pretest probability of deep venous thrombosis. *Br J Haematol.* 2002;118(1):275-277.
78. Ruiz-Giménez N, Frieria A, Artieda P, et al. Rapid D-dimer test combined a clinical model for deep vein thrombosis. Validation with ultrasonography and clinical follow-up in 383 patients. *Thromb Haemost.* 2004;91(6):1237-1246.
79. Kearon C, Ginsberg JS, Douketis J, et al. Management of suspected deep venous thrombosis in outpatients by using clinical assessment and D-dimer testing. *Ann Intern Med.* 2001;135(2):108-111.
80. Kearon C, Ginsberg JS, Douketis J, et al. A randomized trial of diagnostic strategies after normal proximal vein ultrasonography for suspected deep venous thrombosis: D-dimer testing compared with repeated ultrasonography. *Ann Intern Med.* 2005;142(7):490-496.
81. Dewar C, Selby C, Jamieson K, Rogers S. Emergency department nurse-based outpatient diagnosis of DVT using an evidence-based protocol. *Emerg Med J.* 2008;25(7):411-416.
82. Elf JL, Strandberg K, Nilsson C, Svensson PJ. Clinical probability assessment and D-dimer determination in patients with suspected deep vein thrombosis, a prospective multicenter management study. *Thromb Res.* 2009;123(4):612-616.
83. Righini M, Paris S, Le Gal G, Laroche JP, Perrier A, Bounameaux H. Clinical relevance of distal deep vein thrombosis. Review of literature data. *Thromb Haemost.* 2006;95(1):56-64.
84. Jaeschke R, Gajewski P, Bates SM, et al. 2009 evidence-based clinical practice guidelines for diagnosing a first episode of lower extremities deep vein thrombosis in ambulatory outpatients. *Pol Arch Med Wewn.* 2009;119(9):541-549.
85. Righini M, Perrier A, De Moerloose P, et al. D-Dimer for venous thromboembolism diagnosis: 20 years later. *J Thromb Haemost.* 2008;6:1059-1071.
86. Righini M, Bounameaux H. Clinical relevance of distal deep vein thrombosis. *Curr Opin Pulm Med.* 2008;14(5):408-413.
87. Atri M, Herba MJ, Reinhold C, et al. Accuracy of sonography in the evaluation of calf deep vein thrombosis in both postoperative surveillance and symptomatic patients. *AJR Am J Roentgenol.* 1996;166(6):1361-1367.
88. Baxter GM, McKechnie S, Duffy P. Colour Doppler ultrasound in deep venous thrombosis: a comparison with venography. *Clin Radiol.* 1990;42(1):32-36.
89. Baxter GM, Duffy P, Partridge E. Colour flow imaging of calf vein thrombosis. *Clin Radiol.* 1992;46(3):198-201.
90. Belcaro GV, Laurora G, Cesarone MR, Errichi BM. Colour duplex scanning and phlebography in deep vein thrombosis. *Panminerva Med.* 1992;34(1):1-3.
91. Bendick PJ, Glover JL, Holden RW, Dillely RS. Pitfalls of the Doppler examination for venous thrombosis. *Am Surg.* 1983;49(6):320-323.
92. Biondetti PR, Vigo M, Tomasella G, Prandoni P. Diagnosis of deep venous thrombosis of the legs: accuracy of ultrasonography using vein compression [in Italian]. *Radiol Med (Torino).* 1990;80(4):463-468.

93. Bradley MJ, Spencer PA, Alexander L, Milner GR. Colour flow mapping in the diagnosis of the calf deep vein thrombosis. *Clin Radiol*. 1993;47(6):399-402.
94. Burke P, Fitzgerald P, Kee S, et al. Duplex imaging for deep vein thrombosis: is it sufficient? *J Ir Coll Physicians Surg*. 1994;23:105-107.
95. Cogo A, Lensing AW, Prandoni P, Büller HR, Girolami A, ten Cate JW. Comparison of real-time B-mode ultrasonography and Doppler ultrasound with contrast venography in the diagnosis of venous thrombosis in symptomatic outpatients. *Thromb Haemost*. 1993;70(3):404-407.
96. de Laveaucoupet J, Morel MP, Philippoteau C, Simoneau G, Musset D. [Diagnostic value of the combination of echography-plethysmography in deep venous thromboses of the legs]. *Ann Radiol (Paris)*. 1989;32(6):447-454.
97. Elias A. Discrepancies between venography and real time B mode ultrasound imaging in the diagnosis of deep vein thrombosis [abstract]. *Thromb Haemost*. 1987:24.
98. Forbes K, Stevenson AJ. The use of power Doppler ultrasound in the diagnosis of isolated deep venous thrombosis of the calf. *Clin Radiol*. 1998;53(10):752-754.
99. Grobéty M, Depairon M, Essinger A, Bizzini G, Luthy JC, Yersin B. [Value of Doppler ultrasonic studies in the diagnosis of deep venous thrombosis of the lower limbs]. *Schweiz Med Wochenschr*. 1996;126(27-28):1196-1201.
100. Guazzaloca G, Palareti G, Legnani C, et al. Deep venous thrombosis. Evaluation of a non-invasive diagnostic procedure based on compression ultrasonography and measurement of D-dimer plasma levels [in Italian]. *Minerva Cardioangiol*. 1997;45(6):259-266.
101. Habscheid W, Höhmann M, Wilhelm T, Epping J. Real-time ultrasound in the diagnosis of acute deep venous thrombosis of the lower extremity. *Angiology*. 1990;41(8):599-608.
102. Kalodiki E, Calahoras L, Nicolaides AN. Make it easy: examination of the duplex system. *Phlebology*. 1993;8(1):17-21.
103. Labropoulos N, Leon M, Kalodiki E, al Kutoubi A, Chan P, Nicolaides AN. Colour flow duplex scanning in suspected acute deep vein thrombosis; experience with routine use. *Eur J Vasc Endovasc Surg*. 1995;9(1):49-52.
104. Lensing AW, Prandoni P, Brandjes D, et al. Detection of deep-vein thrombosis by real-time B-mode ultrasonography. *N Engl J Med*. 1989;320(6):342-345.
105. Leven H, Hassan HA. Ultrasonic diagnosis of iliofemoral venous thrombosis: merits and disadvantages. *Phlebology*. 1990;5:107-112.
106. Lindqvist R. Ultrasound as a complementary diagnostic method in deep vein thrombosis of the leg. *Acta Med Scand*. 1977;201(5):435-438.
107. Mattos MA, Londrey GL, Leutz DW, et al. Color-flow duplex scanning for the surveillance and diagnosis of acute deep venous thrombosis. *J Vasc Surg*. 1992;15(2):366-375.
108. McCandless ME, Young JR, Swift CL. Noninvasive diagnosis of clinically suspected deep venous thrombosis. *Cleve Clin Q*. 1985;52(4):555-560.
109. Miller N, Satin R, Tousignant L, Sheiner NM. A prospective study comparing duplex scan and venography for diagnosis of lower-extremity deep vein thrombosis. *Cardiovasc Surg*. 1996;4(4):505-508.
110. Mitchell DC, Grasty MS, Stebbings WS, et al. Comparison of duplex ultrasonography and venography in the diagnosis of deep venous thrombosis. *Br J Surg*. 1991;78(5):611-613.
111. Monreal M, Montserrat E, Salvador R, et al. Real-time ultrasound for diagnosis of symptomatic venous thrombosis and for screening of patients at risk: correlation with ascending conventional venography. *Angiology*. 1989;40(6):527-533.
112. Puls R, Hosten N, Böck JS, et al. Signal-enhanced color Doppler sonography of deep venous thrombosis in the lower limbs and pelvis. *J Ultrasound Med*. 1999;18(3):185-190.
113. Quintavalla R, Larini P, Miselli A, et al. Duplex ultrasound diagnosis of symptomatic proximal deep vein thrombosis of lower limbs. *Eur J Radiol*. 1992;15(1):32-36.
114. Robertson PL, Goergen SK, Waugh JR, Fabiny RP. Colour-assisted compression ultrasound in the diagnosis of calf deep venous thrombosis. *Med J Aust*. 1995;163(10):515-518.
115. Robertson PL, Berlangieri SU, Goergen SK, et al. Comparison of ultrasound and blood pool scintigraphy in the diagnosis of lower limb deep venous thrombosis. *Clin Radiol*. 1994;49(6):382-390.
116. Rose SC, Zwiebel WJ, Nelson BD, et al. Symptomatic lower extremity deep venous thrombosis: accuracy, limitations, and role of color duplex flow imaging in diagnosis. *Radiology*. 1990;175(3):639-644.
117. Rosier H, Bellin MF, Bousquet JC, Radier C, Lang T, Grellet J. Prospective study of echography versus phlebography in the detection of sural venous thrombosis [in French]. *J Radiol*. 1992;73(11):579-584.
118. Savy-Stortz C, Nové-Josserand R, Dubost A, Durand DV, Levrat R. Venous ultrasonography coupled with continuous Doppler in the diagnosis of deep venous thrombosis of the lower limbs. Evaluation in symptomatic patients [in French]. *Presse Med*. 1995;24(7):341-344.
119. Simons GR, Skibo LK, Polak JF, Creager MA, Klapac-Fay JM, Goldhaber SZ. Utility of leg ultrasonography in suspected symptomatic isolated calf deep venous thrombosis. *Am J Med*. 1995;99(1):43-47.
120. Size GP, Peterson DL, Laubach M, et al. Our experience with venous duplex imaging for the diagnosis of symptomatic deep vein thrombosis. *J Vasc Technol*. 1993;17(3/4):87-89.
121. Yucel EK, Fisher JS, Eggin TK, Geller SC, Waltman AC. Isolated calf venous thrombosis: diagnosis with compression US. *Radiology*. 1991;179(2):443-446.
122. Zhou MK, Pu LP, Wang ZG, Wang SH. Doppler ultrasonic diagnosis for deep venous thrombosis of lower limbs. *Chin Med J (Engl)*. 1990;103(4):271-273.
123. Johnson SA, Stevens SM, Woller SC, et al. Risk of deep vein thrombosis following a single negative whole-leg compression ultrasound: a systematic review and meta-analysis. *JAMA*. 2010;303(5):438-445.
124. Palareti G, Cosmi B, Lessiani G, et al. Evolution of untreated calf deep-vein thrombosis in high risk symptomatic outpatients: the blind, prospective CALTHRO study. *Thromb Haemost*. 2010;104(5):1063-1070.
125. Thomas SM, Goodacre SW, Sampson FC, van Beek EJ. Diagnostic value of CT for deep vein thrombosis: results of a systematic review and meta-analysis. *Clin Radiol*. 2008;63(3):299-304.
126. Byun SS, Kim JH, Kim YJ, Jeon YS, Park CH, Kim WH. Evaluation of deep vein thrombosis with multidetector row CT after orthopedic arthroplasty: a prospective study for comparison with Doppler sonography. *Korean J Radiol*. 2008;9(1):59-66.
127. Rhee KH, Iyer RS, Cha S, et al. Benefit of CT venography for the diagnosis of thromboembolic disease. *Clin Imaging*. 2007;31(4):253-258.
128. Goodman LR, Stein PD, Matta F, et al. CT venography and compression sonography are diagnostically equivalent: data from PLOPED II. *AJR Am J Roentgenol*. 2007;189(5):1071-1076.
129. Garcia-Bolado A, Del Cura JL. CT venography vs ultrasound in the diagnosis of thromboembolic disease in patients with clinical suspicion of pulmonary embolism. *Emerg Radiol*. 2007;14(6):403-409.

130. Kim T, Murakami T, Hori M, Kumano S, Sakon M, Nakamura H. Efficacy of multi-slice helical CT venography for the diagnosis of deep venous thrombosis: comparison with venous sonography. *Radiat Med.* 2004;22(2):77-81.
131. Lim KE, Hsu WC, Hsu YY, Chu PH, Ng CJ. Deep venous thrombosis: comparison of indirect multidetector CT venography and sonography of lower extremities in 26 patients. *Clin Imaging.* 2004;28(6):439-444.
132. Lim KE, Hsu YY, Hsu WC, Huang CC. Combined computed tomography venography and pulmonary angiography for the diagnosis PE and DVT in the ED. *Am J Emerg Med.* 2004;22(4):301-306.
133. Begemann PG, Bonacker M, Kemper J, et al. Evaluation of the deep venous system in patients with suspected pulmonary embolism with multi-detector CT: a prospective study in comparison to Doppler sonography. *J Comput Assist Tomogr.* 2003;27(3):399-409.
134. Loud PA, Katz DS, Bruce DA, Klippenstein DL, Grossman ZD. Deep venous thrombosis with suspected pulmonary embolism: detection with combined CT venography and pulmonary angiography. *Radiology.* 2001;219(2):498-502.
135. Peterson DA, Kazerooni EA, Wakefield TW, et al. Computed tomographic venography is specific but not sensitive for diagnosis of acute lower-extremity deep venous thrombosis in patients with suspected pulmonary embolus. *J Vasc Surg.* 2001;34(5):798-804.
136. Yoshida S, Akiba H, Tamakawa M, Yama N, Takeda M, Hareyama M. Spiral CT venography of the lower extremities by injection via an arm vein in patients with leg swelling. *Br J Radiol.* 2001;74(887):1013-1016.
137. Ghaye B, Szapiro D, Willems V, Dondelinger RF. Combined CT venography of the lower limbs and spiral CT angiography of pulmonary arteries in acute pulmonary embolism: preliminary results of a prospective study. *JBR-BTR.* 2000;83(5):271-278.
138. Cham MD, Yankelevitz DF, Shaham D, et al; The Pulmonary Angiography-Indirect CT Venography Cooperative Group. Deep venous thrombosis: detection by using indirect CT venography. *Radiology.* 2000;216(3):744-751.
139. Garg K, Kemp JL, Wojcik D, et al. Thromboembolic disease: comparison of combined CT pulmonary angiography and venography with bilateral leg sonography in 70 patients. *AJR Am J Roentgenol.* 2000;175(4):997-1001.
140. Coche EE, Hamoir XL, Hammer FD, Hainaut P, Goffette PP. Using dual-detector helical CT angiography to detect deep venous thrombosis in patients with suspicion of pulmonary embolism: diagnostic value and additional findings. *AJR Am J Roentgenol.* 2001;176(4):1035-1039.
141. Duwe KM, Shiao M, Budorick NE, Austin JH, Berkmen YM; American Roentgen Ray Society. Evaluation of the lower extremity veins in patients with suspected pulmonary embolism: a retrospective comparison of helical CT venography and sonography. 2000 ARRS Executive Council Award I. *AJR Am J Roentgenol.* 2000;175(6):1525-1531.
142. Shah AA, Buckshee N, Yankelevitz DF, Henschke CI. Assessment of deep venous thrombosis using routine pelvic CT. *AJR Am J Roentgenol.* 1999;173(3):659-663.
143. Baldt MM, Zontsich T, Stümpflen A, et al. Deep venous thrombosis of the lower extremity: efficacy of spiral CT venography compared with conventional venography in diagnosis. *Radiology.* 1996;200(2):423-428.
144. Sampson FC, Goodacre SW, Thomas SM, van Beek EJ. The accuracy of MRI in diagnosis of suspected deep vein thrombosis: systematic review and meta-analysis. *Eur Radiol.* 2007;17(1):175-181.
145. Cantwell CP, Cradock A, Bruzzi J, Fitzpatrick P, Eustace S, Murray JG. MR venography with true fast imaging with steady-state precession for suspected lower-limb deep vein thrombosis. *J Vasc Interv Radiol.* 2006;17(11 pt 1):1763-1769.
146. Fraser DG, Moody AR, Morgan PS, Martel AL, Davidson I. Diagnosis of lower-limb deep venous thrombosis: a prospective blinded study of magnetic resonance direct thrombus imaging. *Ann Intern Med.* 2002;136(2):89-98.
147. Fraser DG, Moody AR, Davidson IR, Martel AL, Morgan PS. Deep venous thrombosis: diagnosis by using venous enhanced subtracted peak arterial MR venography versus conventional venography. *Radiology.* 2003;226(3):812-820.
148. Sica GT, Pugach ME, Koniaris LS, et al. Isolated calf vein thrombosis: comparison of MR venography and conventional venography after initial sonography in symptomatic patients. *Acad Radiol.* 2001;8(9):856-863.
149. Jensen AD, Borris LC, Christiansen TM, Lundorf E. Accuracy of magnetic resonance imaging in the diagnosis of deep vein thrombosis in asymptomatic patients with injuries of the lower extremity. A pilot study. *Thromb Res.* 2001;101(6):423-426.
150. Catalano C, Pavone P, Laghi A, et al. Role of MR venography in the evaluation of deep venous thrombosis. *Acta Radiol.* 1997;38(5):907-912.
151. Laissy JP, Cinqualbre A, Loshkajian A, et al. Assessment of deep venous thrombosis in the lower limbs and pelvis: MR venography versus duplex Doppler sonography. *AJR Am J Roentgenol.* 1996;167(4):971-975.
152. Larcom PG, Lotke PA, Steinberg ME, Holland G, Foster S. Magnetic resonance venography versus contrast venography to diagnose thrombosis after joint surgery. *Clin Orthop Relat Res.* 1996;(331):209-215.
153. Evans AJ, Sostman HD, Witty LA, et al. Detection of deep venous thrombosis: prospective comparison of MR imaging and sonography. *J Magn Reson Imaging.* 1996;6(1):44-51.
154. Evans AJ, Sostman HD, Knelson MH, et al. 1992 ARRS Executive Council Award. Detection of deep venous thrombosis: prospective comparison of MR imaging with contrast venography. *AJR Am J Roentgenol.* 1993;161(1):131-139.
155. Carpenter JP, Holland GA, Baum RA, Owen RS, Carpenter JT, Cope C. Magnetic resonance venography for the detection of deep venous thrombosis: comparison with contrast venography and duplex Doppler ultrasonography. *J Vasc Surg.* 1993;18(5):734-741.
156. Spritzer CE, Norconk JJ Jr, Sostman HD, Coleman RE. Detection of deep venous thrombosis by magnetic resonance imaging. *Chest.* 1993;104(1):54-60.
157. Pope CF, Dietz MJ, Ezekowitz MD, Gore JC. Technical variables influencing the detection of acute deep vein thrombosis by magnetic resonance imaging. *Magn Reson Imaging.* 1991;9(3):379-388.
158. Vukov LF, Berquist TH, King BF. Magnetic resonance imaging for calf deep venous thrombophlebitis. *Ann Emerg Med.* 1991;20(5):497-499.
159. Erdman WA, Jayson HT, Redman HC, Miller GL, Parkey RW, Peshock RW. Deep venous thrombosis of extremities: role of MR imaging in the diagnosis. *Radiology.* 1990;174(2):425-431.
160. Koopman MM, Jongbloets L, Lensing AW, Buller H, ten Cate JW. Clinical utility of a quantitative B-mode ultrasonography method in patients with suspected recurrent deep vein thrombosis (DVT). *Thromb Haemost.* 1993;69:285a.
161. Prandoni P, Cogo A, Bernardi E, et al. A simple ultrasound approach for detection of recurrent proximal-vein thrombosis. *Circulation.* 1993;88(4 pt 1):1730-1735.

162. Villalta S, Rossi L, Bernardi E, et al. Serial compression ultrasonography in the diagnostic approach of patients with clinically suspected recurrent deep vein thrombosis. Interim report of an ongoing study [abstract]. *Thromb Haemost.* 1997;78:588.
163. Prandoni P, Lensing AWA, Bernardi E, Villalta S, Bagatella P, Girolami A; DERECUS Investigators Group. The diagnostic value of compression ultrasonography in patients with suspected recurrent deep vein thrombosis. *Thromb Haemost.* 2002;88(3):402-406.
164. Le Gal G, Kovacs MJ, Carrier M, et al. Validation of a diagnostic approach to exclude recurrent venous thromboembolism. *J Thromb Haemost.* 2009;7(5):752-759.
165. Bates SM, Kearon C, Kahn SR, et al. A negative D-dimer excludes recurrent deep vein thrombosis: results of a multicentre management trial [abstract]. *Blood.* 2007;110:214a.
166. Prandoni P, Tormene D, Dalla Valle F, Concolato A, Pesavento R. D-dimer as an adjunct to compression ultrasonography in patients with suspected recurrent deep vein thrombosis. *J Thromb Haemost.* 2007;5(5):1076-1077.
167. Aguilar C, del Villar V. Combined D-dimer and clinical probability are useful for exclusion of recurrent deep venous thrombosis. *Am J Hematol.* 2007;82(1):41-44.
168. Rathbun SW, Whitsett TL, Raskob GE. Negative D-dimer result to exclude recurrent deep venous thrombosis: a management trial. *Ann Intern Med.* 2004;141(11):839-845.
169. Hull RD, Carter CJ, Jay RM, et al. The diagnosis of acute, recurrent, deep-vein thrombosis: a diagnostic challenge. *Circulation.* 1983;67(4):901-906.
170. Albrechtsson U, Olsson CG. Thrombosis after phlebography: a comparison of two contrast media. *Cardiovasc Radiol.* 1979;2(1):9-18.
171. Bettmann MA, Salzman EW, Rosenthal D, et al. Reduction of venous thrombosis complicating phlebography. *AJR Am J Roentgenol.* 1980;134(6):1169-1172.
172. Laerum F, Holm HA. Postphlebographic thrombosis: a double-blind study with methylglucamine metrizoate and metrizamide. *Radiology.* 1981;140(3):651-654.
173. Heijboer H, Jongbloets LM, Büller HR, Lensing AW, ten Cate JW. Clinical utility of real-time compression ultrasonography for diagnostic management of patients with recurrent venous thrombosis. *Acta Radiol.* 1992;33(4):297-300.
174. Cronan JJ, Leen V. Recurrent deep venous thrombosis: limitations of US. *Radiology.* 1989;170(3 pt 1):739-742.
175. Piovella F, Crippa L, Barone M, et al. Normalization rates of compression ultrasonography in patients with a first episode of deep vein thrombosis of the lower limbs: association with recurrence and new thrombosis. *Haematologica.* 2002;87(5):515-522.
176. Tan M, Velthuis SI, Westerbeek RE, van Rooden CJ, van der Meer FJ, Huisman MV. High percentage of non-diagnostic compression ultrasonography results and the diagnosis of ipsilateral recurrent proximal deep vein thrombosis. *J Thromb Haemost.* 2010;8(4):848-850.
177. Linkins LA, Stretton R, Probyn L, Kearon C. Interobserver agreement on ultrasound measurements of residual vein diameter, thrombus echogenicity and Doppler venous flow in patients with previous venous thrombosis. *Thromb Res.* 2006;117(3):241-247.
178. Linkins LA, Pasquale P, Paterson S, Kearon C. Change in thrombus length on venous ultrasound and recurrent deep vein thrombosis. *Arch Intern Med.* 2004;164(16):1793-1796.
179. Elias A, Bonfils S, Daoud-Elias M, et al. Influence of long term oral anticoagulants upon prothrombin fragment 1 + 2, thrombin-antithrombin III complex and D-Dimer levels in patients affected by proximal deep vein thrombosis. *Thromb Haemost.* 1993;69(4):302-305.
180. Sié P, Cadroy Y, Elias A, Boccalon H, Boneu B. D-dimer levels in patients with long-term antecedents of deep venous thrombosis. *Thromb Haemost.* 1994;72(1):161-162.
181. Westerbeek RE, Van Rooden CJ, Tan M, et al. Magnetic resonance direct thrombus imaging of the evolution of acute deep vein thrombosis of the leg. *J Thromb Haemost.* 2008;6(7):1087-1092.
182. Ray JG, Chan WS. Deep vein thrombosis during pregnancy and the puerperium: a meta-analysis of the period of risk and the leg of presentation. *Obstet Gynecol Surv.* 1999;54(4):265-271.
183. Chan WS, Spencer FA, Ginsberg JS. Anatomic distribution of deep vein thrombosis in pregnancy. *CMAJ.* 2010;182(7):657-660.
184. Chan W-S, Lee A, Spencer FA, et al. Predicting deep venous thrombosis in pregnancy: out in "LEFT" field? *Ann Intern Med.* 2009;151(2):85-92.
185. Chan WS, Lee A, Spencer FA, et al. D-dimer testing in pregnant patients: towards determining the next 'level' in the diagnosis of deep vein thrombosis. *J Thromb Haemost.* 2010;8(5):1004-1011.
186. Chan WS, Chunilal S, Lee A, Crowther M, Rodger M, Ginsberg JS. A red blood cell agglutination D-dimer test to exclude deep venous thrombosis in pregnancy. *Ann Intern Med.* 2007;147(3):165-170.
187. Le Gal G, Righini M, Kercret L, et al. Diagnosis of deep vein thrombosis by compression ultrasonography during pregnancy and the postpartum period: a management study [abstract]. *J Thromb Haemost.* 2009;7:1103.
188. Ginsberg JS, Hirsh J, Rainbow AJ, Coates G. Risks to the fetus of radiologic procedures used in the diagnosis of maternal venous thromboembolic disease. *Thromb Haemost.* 1989;61(2):189-196.
189. Ratnapalan S, Bentur Y, Koren G. "Doctor, will that x-ray harm my unborn child?". *CMAJ.* 2008;179(12):1293-1296.
190. *Prenatal Radiation Exposure: A Fact Sheet for Physicians.* Atlanta, GA: Center for Disease Control and Prevention (CDC); 2005.
191. Doll R, Wakeford R. Risk of childhood cancer from fetal irradiation. *Br J Radiol.* 1997;70:130-139.
192. Ray JG, Schull MJ, Urquia ML, You JJ, Guttmann A, Vermeulen MJ. Major radiodiagnostic imaging in pregnancy and the risk of childhood malignancy: a population-based cohort study in Ontario. *PLoS Med.* 2010;7(9):e1000337.
193. Barrellier MT, Lezin B, Monsallier JM. Isolated iliac deep venous thrombosis. Study of 48 cases seen in 7 years among 18,297 echo-Doppler evaluations of the lower limbs [in French]. *J Mal Vasc.* 2001;26(5):290-298.
194. Scarsbrook AF, Evans AL, Owen AR, Gleeson FV. Diagnosis of suspected venous thromboembolic disease in pregnancy. *Clin Radiol.* 2006;61(1):1-12.
195. Palmgren J, Kirkinen P. Venous circulation in the maternal lower limb: a Doppler study with the Valsalva maneuver. *Ultrasound Obstet Gynecol.* 1996;8(2):93-97.
196. Macklon NS, Greer IA, Bowman AW. An ultrasound study of gestational and postural changes in the deep venous system of the leg in pregnancy. *Br J Obstet Gynaecol.* 1997;104(2):191-197.
197. Duddy MJ, McHugo JM. Duplex ultrasound of the common femoral vein in pregnancy and puerperium. *Br J Radiol.* 1991;64(765):785-791.
198. Le Gal G, Prins AM, Righini M, et al. Diagnostic value of a negative single complete compression ultrasound of the lower limbs to exclude the diagnosis of deep venous throm-

- bosis in pregnant or postpartum women: a retrospective hospital-based study. *Thromb Res.* 2006;118(6):691-697.
199. Chan WS, Ginsberg JS. Diagnosis of venous thromboembolism in pregnancy: a study in extrapolation or a science in evolution? *Expert Rev Cardiovasc Ther.* 2009;7(12):1479-1482.
 200. Nolan TE, Smith RP, Devoe LD. Maternal plasma D-dimer levels in normal and complicated pregnancies. *Obstet Gynecol.* 1993;81(2):235-238.
 201. Francalanci I, Comeglio P, Liotta AA, et al. D-dimer concentrations during normal pregnancy, as measured by ELISA. *Thromb Res.* 1995;78(5):399-405.
 202. Ballegeer V, Mombaerts P, Declercq PJ, Spitz B, Van Assche FA, Collen D. Fibrinolytic response to venous occlusion and fibrin fragment D-dimer levels in normal and complicated pregnancy. *Thromb Haemost.* 1987;58(4):1030-1032.
 203. Morse M. Establishing a normal range for D-dimer levels through pregnancy to aid in the diagnosis of pulmonary embolism and deep vein thrombosis. *J Thromb Haemost.* 2004;2(7):1202-1204.
 204. Chan WSCS, Bates S, Naguit I, Sood R, Johnston M. The prevalence of positive soluble fibrin and D-dimer results in health asymptomatic pregnant women [abstract]. *Blood.* 1999;94:20a.
 205. Kline JA, Williams GW, Hernandez-Nino J. D-dimer concentrations in normal pregnancy: new diagnostic thresholds are needed. *Clin Chem.* 2005;51(5):825-829.
 206. Kovac M, Mikovic Z, Rakicevic L, et al. The use of D-dimer with new cutoff can be useful in diagnosis of venous thromboembolism in pregnancy. *Eur J Obstet Gynecol Reprod Biol.* 2010;148(1):27-30.
 207. Rademaker J, Griesshaber V, Hidajat N, Oestmann JW, Felix R. Combined CT pulmonary angiography and venography for diagnosis of pulmonary embolism and deep vein thrombosis: radiation dose. *J Thorac Imaging.* 2001;16(4):297-299.
 208. Torkzad MR, Bremme K, Hellgren M, et al. Magnetic resonance imaging and ultrasonography in diagnosis of pelvic vein thrombosis during pregnancy. *Thromb Res.* 2010;126(2):107-112.
 209. Roos DB, Edgar J. Edgar J. Poth Lecture. Thoracic outlet syndromes: update 1987. *Am J Surg.* 1987;154(6):568-573.
 210. Bernardi E, Pesavento R, Prandoni P. Upper extremity deep venous thrombosis. *Semin Thromb Hemost.* 2006;32(7):729-736.
 211. Spencer FA, Emery C, Lessard D, Goldberg RJ; Worcester Venous Thromboembolism Study. Upper extremity deep vein thrombosis: a community-based perspective. *Am J Med.* 2007;120(8):678-684.
 212. Isma N, Svensson PJ, Gottsäter A, Lindblad B. Upper extremity deep venous thrombosis in the population-based Malmö thrombophilia study (MATS). Epidemiology, risk factors, recurrence risk, and mortality. *Thromb Res.* 2010;125(6):e335-e338.
 213. Joffe HV, Kucher N, Tapson VF, Goldhaber SZ; Deep Vein Thrombosis (DVT) FREE Steering Committee. Upper extremity deep vein thrombosis: a prospective registry of 592 patients. *Circulation.* 2004;110(12):1605-1611.
 214. Coon WW, Willis PW III. Thrombosis of axillary and subclavian veins. *Arch Surg.* 1967;94(5):657-663.
 215. Horattas MC, Wright DJ, Fenton AH, et al. Changing concepts of deep venous thrombosis of the upper extremity—report of a series and review of the literature. *Surgery.* 1988;104(3):561-567.
 216. Prandoni P, Polistena P, Bernardi E, et al. Upper-extremity deep vein thrombosis. Risk factors, diagnosis, and complications. *Arch Intern Med.* 1997;157(1):57-62.
 217. Constans J, Salmi LR, Sevestre-Pietri MA, et al. A clinical prediction score for upper extremity deep venous thrombosis. *Thromb Haemost.* 2008;99(1):202-207.
 218. Merminod T, Pellicciotta S, Bounameaux H. Limited usefulness of D-dimer in suspected deep vein thrombosis of the upper extremities. *Blood Coagul Fibrinolysis.* 2006;17(3):225-226.
 219. Sullivan ED, Peter DJ, Cranley JJ. Real-time B-mode venous ultrasound. *J Vasc Surg.* 1984;1(3):465-471.
 220. Di Nisio M, Van Sluis GL, Bossuyt PM, Büller HR, Porreca E, Rutjes AW. Accuracy of diagnostic tests for clinically suspected upper extremity deep vein thrombosis: a systematic review. *J Thromb Haemost.* 2010;8(4):684-692.
 221. Baarslag HJ, Van Beek EJ, Reekers JA. Magnetic resonance venography in consecutive patients with suspected deep vein thrombosis of the upper extremity: initial experience. *Acta Radiol.* 2004;45(1):38-43.
 222. Baxter GM, Kincaid W, Jeffrey RF, Millar GM, Porteous C, Morley P. Comparison of colour Doppler ultrasound with venography in the diagnosis of axillary and subclavian vein thrombosis. *Br J Radiol.* 1991;64(765):777-781.
 223. Falk RL, Smith DF. Thrombosis of upper extremity thoracic inlet veins: diagnosis with duplex Doppler sonography. *AJR Am J Roentgenol.* 1987;149(4):677-682.
 224. Haire WD, Lynch TG, Lund GB, Lieberman RP, Edney JA. Limitations of magnetic resonance imaging and ultrasound-directed (duplex) scanning in the diagnosis of subclavian vein thrombosis. *J Vasc Surg.* 1991;13(3):391-397.
 225. Knudson GJ, Wiedmeyer DA, Erickson SJ, et al. Color Doppler sonographic imaging in the assessment of upper-extremity deep venous thrombosis. *AJR Am J Roentgenol.* 1990;154(2):399-403.
 226. Patel MC, Berman LH, Moss HA, McPherson SJ. Subclavian and internal jugular veins at Doppler US: abnormal cardiac pulsatility and respiratory phasicity as a predictor of complete central occlusion. *Radiology.* 1999;211(2):579-583.
 227. Sottirai VS, Towner K, McDonnell AE, Zarins CK. Diagnosis of upper extremity deep venous thrombosis using noninvasive technique. *Surgery.* 1982;91(5):582-585.
 228. Baarslag HJ, van Beek EJ, Koopman MM, Reekers JA. Prospective study of color duplex ultrasonography compared with contrast venography in patients suspected of having deep venous thrombosis of the upper extremities. *Ann Intern Med.* 2002;136(12):865-872.